

SUPERhip and SUPERhip2 Procedures for Congenital Femoral Deficiency

35

Dror Paley

Introduction

Congenital femoral deficiency (CFD) presents a spectrum of deficiency, deformity and dysplasia of the upper femur, hip joint and acetabulum. The Paley classification divides this spectrum into separate pathoanatomical groups that can be treated using discreetly different operative procedures specific to the pathoanatomy of each type of CFD. The SUPERhip1 procedure is used to reconstruct Paley type 1 CFD cases, while the SUPERhip2 procedure is used to reconstruct Paley type 2 CFD cases.

Brief Clinical History

Classification of Congenital Femur Deficiency [1] (Fig. 35.1)

Type 1: *intact femur* with mobile hip and knee

- (a) normal ossification proximal femur
- (b) delayed ossification proximal femur (neck, subtrochanteric or combined neck subtrochanteric types)

Type 2: *mobile pseudoarthrosis* (greater trochanteric apophysis present), knee usually mobile

- (a) femoral head mobile in acetabulum
- (b) femoral head partially fused to acetabulum
- (c) femoral head and acetabulum completely fused or absent

Type 3: *diaphyseal deficiency* of femur (greater trochanteric apophysis absent)

- (a) distal physis present; knee motion $\geq 45^\circ$
- (b) distal physis present knee motion $< 45^\circ$
- (c) complete deficiency of distal femur or fusion of distal femoral remnant to tibia (distal physis absent)

Type 4: *distal deficiency of femur* (proximal end normal).

D. Paley (✉)

Paley Orthopedic and Spine Institute, St. Mary's
Medical Center, West Palm Beach, FL, USA
e-mail: dpaley@paleyinstitute.org

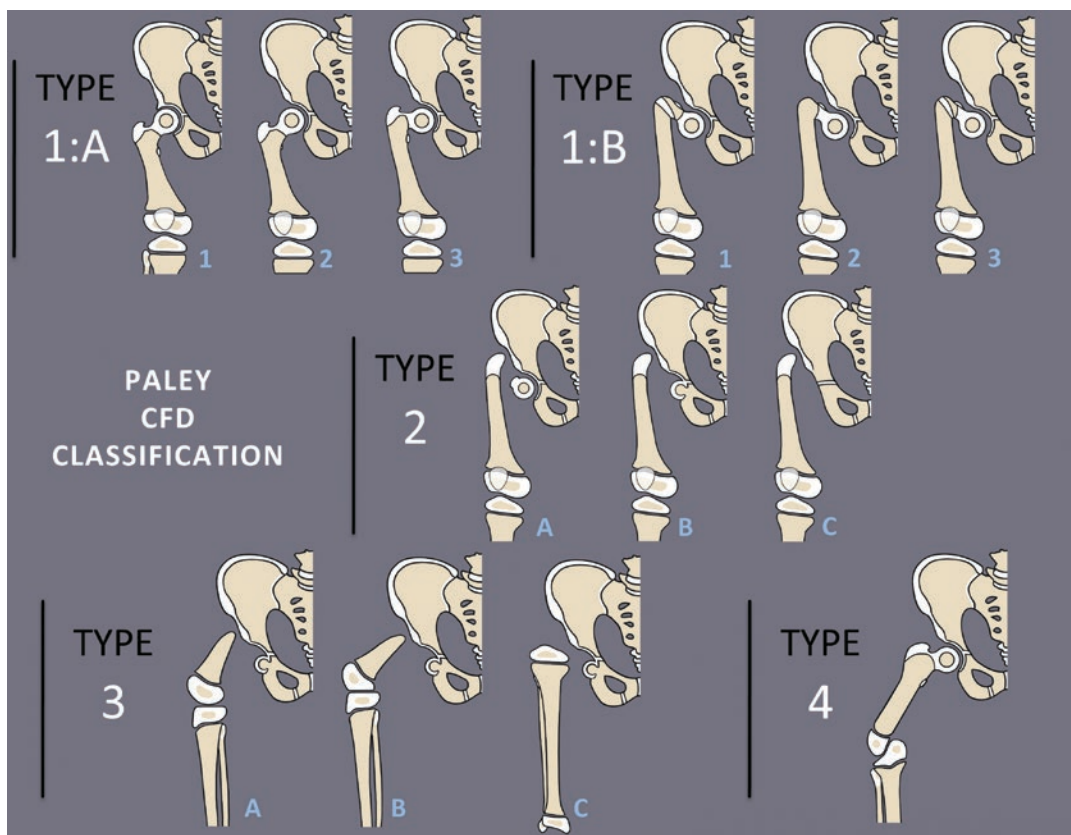


Fig. 35.1 Paley classification of congenital femoral deficiency. (© 2014 The Paley Foundation, with permission. All rights reserved)

Model Paley Type 1b Pathoanatomy [2] (Fig. 35.2)

To understand the complex deformity of the Paley type 1b deformity it is useful to create a simple model consisting of three bone segments: pelvis, proximal femur to the level of the lesser trochanter with a 130° neck shaft angle and greater trochanter at the normal level of the center of the femoral head, and distal femur from the subtrochanteric region to the knee joint. Start by placing the femoral head in the acetabulum anatomically and flexing it 90° . Then abduct the

femur 45° relative to the pelvis, in the flexed position. Next, attach the distal femur to the distal end of the proximal femur with the knee rotated externally 45° . This construct is the model of the Paley 1b CFD. Note that the flexion of the upper femur makes the neck appear retroverted since the normal neck shaft angle points posteriorly. Abducting the proximal femur now makes the neck look in varus from the frontal view, despite the neck shaft angle measuring 130° . Finally, adding the distal femur in external rotation adds actual retroversion to the pseudo retroversion from the flexion and also makes the

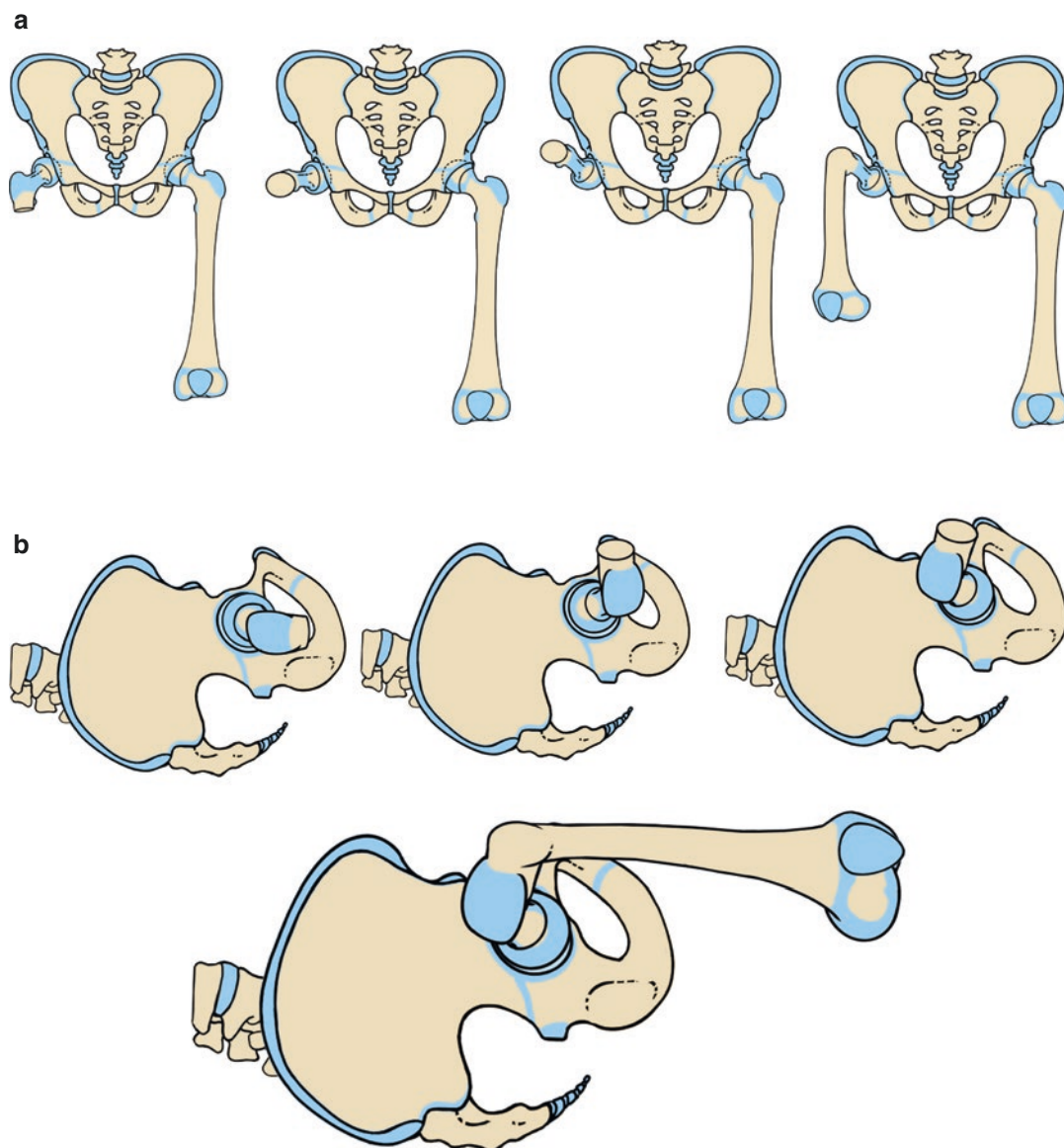


Fig. 35.2 (a) Model of congenital femoral deficiency (CFD) hip deformity, anteroposterior view. Hip neutral (*left*). Hip flexed 90° (*left middle*). Hip abducted in flexion (*right middle*). Distal femur externally rotated and connected to proximal hip flexion, abduction position (*right*). (b) Model of CFD hip deformity, lateral view. Hip neutral (*top left*). Hip flexed 90° (*top middle*). Hip abducted in

flexion (*top right*). Distal femur externally rotated and connected to proximal hip flexion, abduction position (*bottom*). (c) Model of CFD hip deformity, inferior view. Hip neutral (*top left*). Hip flexed 90° (*top right*). Hip abducted in flexion (*bottom*). (© 2014 The Paley Foundation, with permission. All rights reserved)

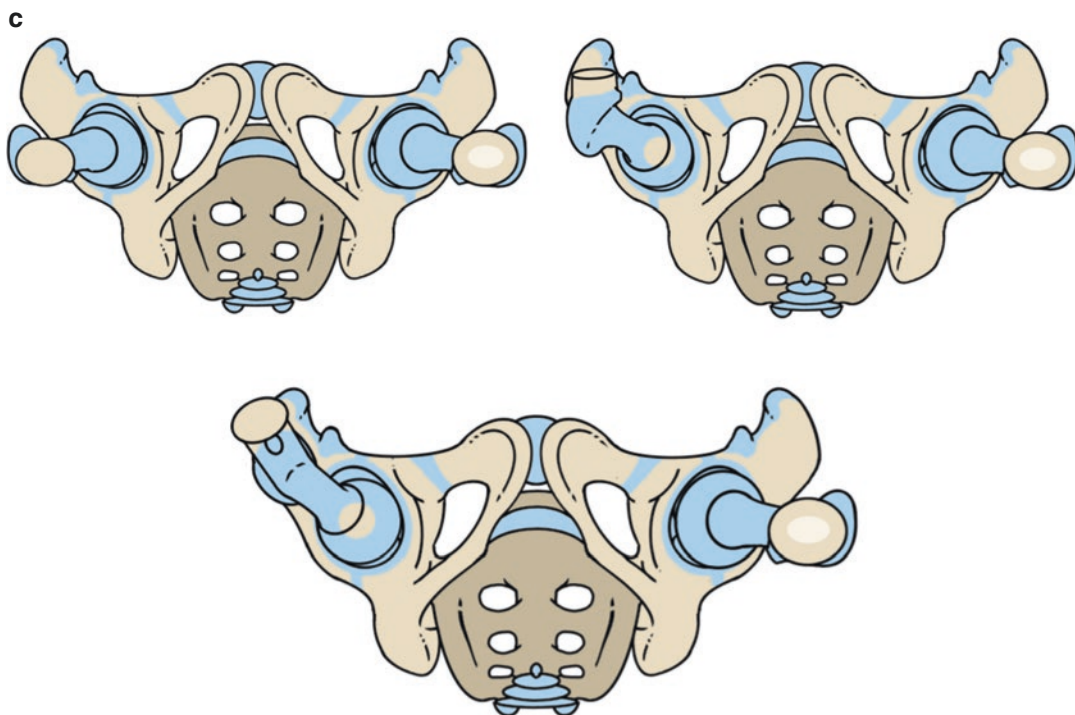


Fig. 35.2 (continued)

pseudo coxa vara appear as a severe coxa vara. The junction of the two parts of the femur form a large bend which can be palpated as a prominent bump. This bump is not the greater trochanter, which is located medial and posterior to the bump. Due to the flexion and abduction of the proximal femur, the greater trochanter lies very close to the ilium and points towards the sacrum. The muscles attaching to the tip of the greater trochanter; gluteus medius and minimus and piriformis are relatively short either primarily or secondary to this persistent position. They act as a tether preventing the proximal femur returning to its normal anatomic position. Similarly the severe

flexion position of the proximal femur is tethered by the primary or secondary contracture of the iliopsoas, tensor fascia lata, rectus femoris and anterior half of the gluteus medius muscles. The combination of this bony deformity with these soft tissue contractures forms the basis for the pathoanatomical approach to surgical correction of the upper femoral deformity associated with some Paley type 1a and all Paley type 1b cases.

Case 1: Paley type 1a CFD (Fig. 35.3)

Eight-year-old girl with CFD with large LLD and failed previous attempts to correct hip deformity and lengthen femur. Fixed adduction, flexion deformity of hip. Knee stable (see Fig. 35.3a, b).

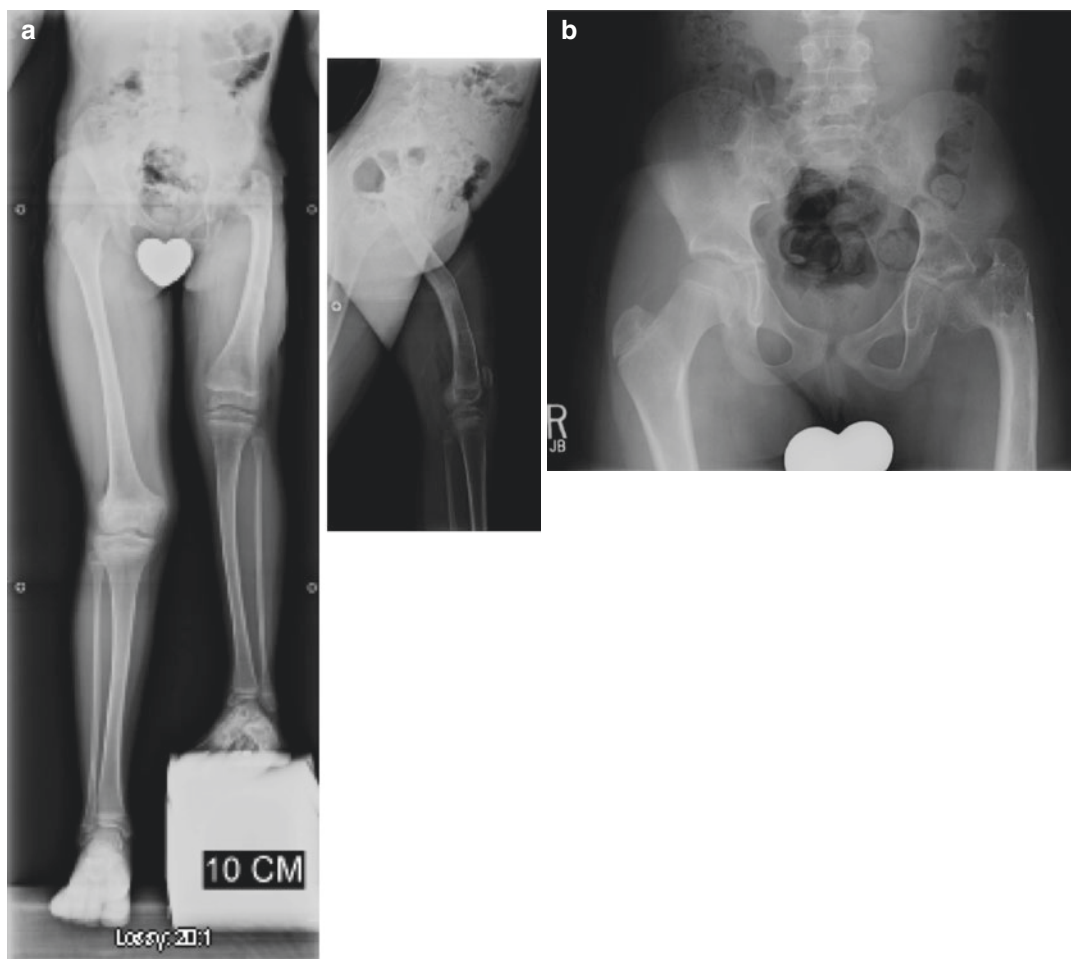


Fig. 35.3 (a) Radiographs of 8 year old girl with left type 1a congenital femoral deficiency and 10 cm leg length discrepancy. Erect leg radiograph (*left*) and lateral femur with knee in full extension. There is severe coxa vara and a very high greater trochanter. There is also mild fibular hemimelia. The knee comes into full extension. (b) Anteroposterior (AP) pelvis radiograph showing the coxa vara and dysplastic acetabulum. (c) Intraoperative fluoroscopic views with blade plate inserted into femoral neck. The varus angulation (angle between plate and femoral shaft) is 45° of varus (*left*) and 15° of flexion. The wires in the femur outline the planned first osteotomy. (d) Intraoperative fluoroscopic views after SUPERhip osteotomy showing correction of the coxa vara (*left*). The greater trochanter is now at the level of the center of the femoral head. The full extent of the acetabular dysplasia

can be appreciated after the valgus osteotomy of the femur (*left*). A periacetabular triple osteotomy was performed to cover the femoral head (*right*). (e) AP pelvis radiograph after healing of the femoral and pelvic osteotomies. (f) Photographs taken during lengthening of the femur and tibia simultaneously with a femoral and tibial external fixator with a hinge connecting the frames at the knee. She was able to be active even with these two external fixators in place. In these pictures she is shown competing in a swim meet. (g) Erect leg radiograph after lengthening. The hip correction and stability are maintained. Hemiepiphysiodesis plates can be seen on the medial proximal and distal tibia to correct valgus. The long lateral radiograph shows full knee extension. (h) Even after two lengthening surgeries her flexibility and range of motion is excellent

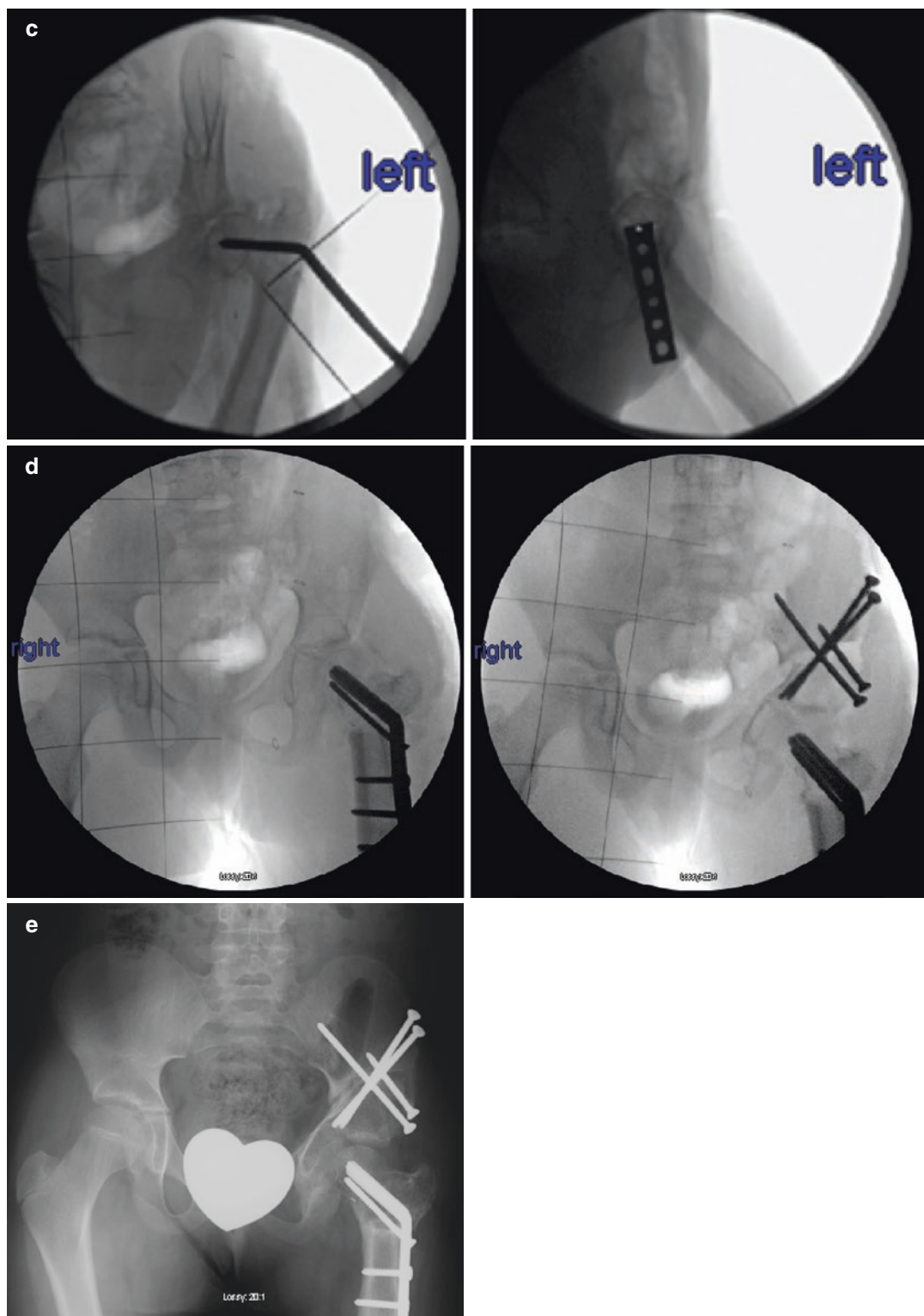


Fig. 35.3 (continued)

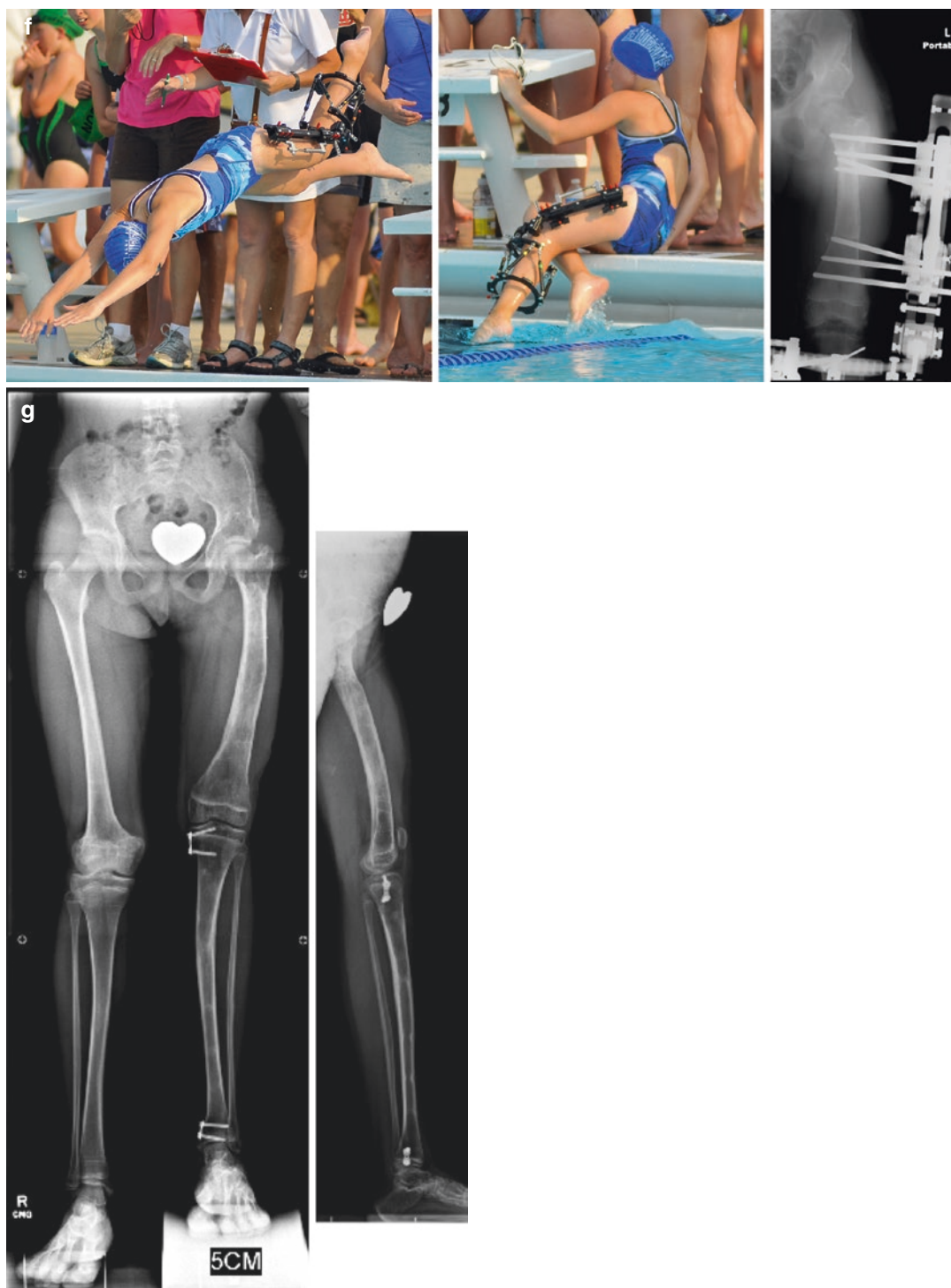

Fig. 35.3 (continued)

h



Fig. 35.3 (continued)

Case 2: Paley type 1b neck type CFD (Fig. 35.4)

Two-year-old girl with right CFD and large leg length discrepancy (LLD).

She has a fixed flexion, external rotation deformity of the hip. Her hip lacks abduction. Her knee has significant anteroposterior instability (see Fig. 35.4a, b).

Case 3: Paley type 1b subtrochanteric type CFD (Fig. 35.5)

Two-year-old girl with left CFD and a large LLD. She has a fixed flexion, adduction, external rotation deformity of the hip. She has a fixed flexion deformity of the knee (see Fig. 35.5a).

Case 4: Paley type 2a CFD (Fig. 35.6)

Six-year-old girl with right CFD and large LLD. Lacks abduction and internal rotation of hip. Knee has mild fixed flexion deformity (see Fig. 35.6a, b).

Preoperative Imaging

Radiographs of the lower limbs are taken to assess leg length discrepancy, evaluate the hip and knee deformities, femoral and acetabular dysplasia [3]. In children that can stand still, an anteroposterior (AP) radiograph is taken standing on a lift of known magnitude to approximately level the pelvis (see Fig. 35.3a). In infants the

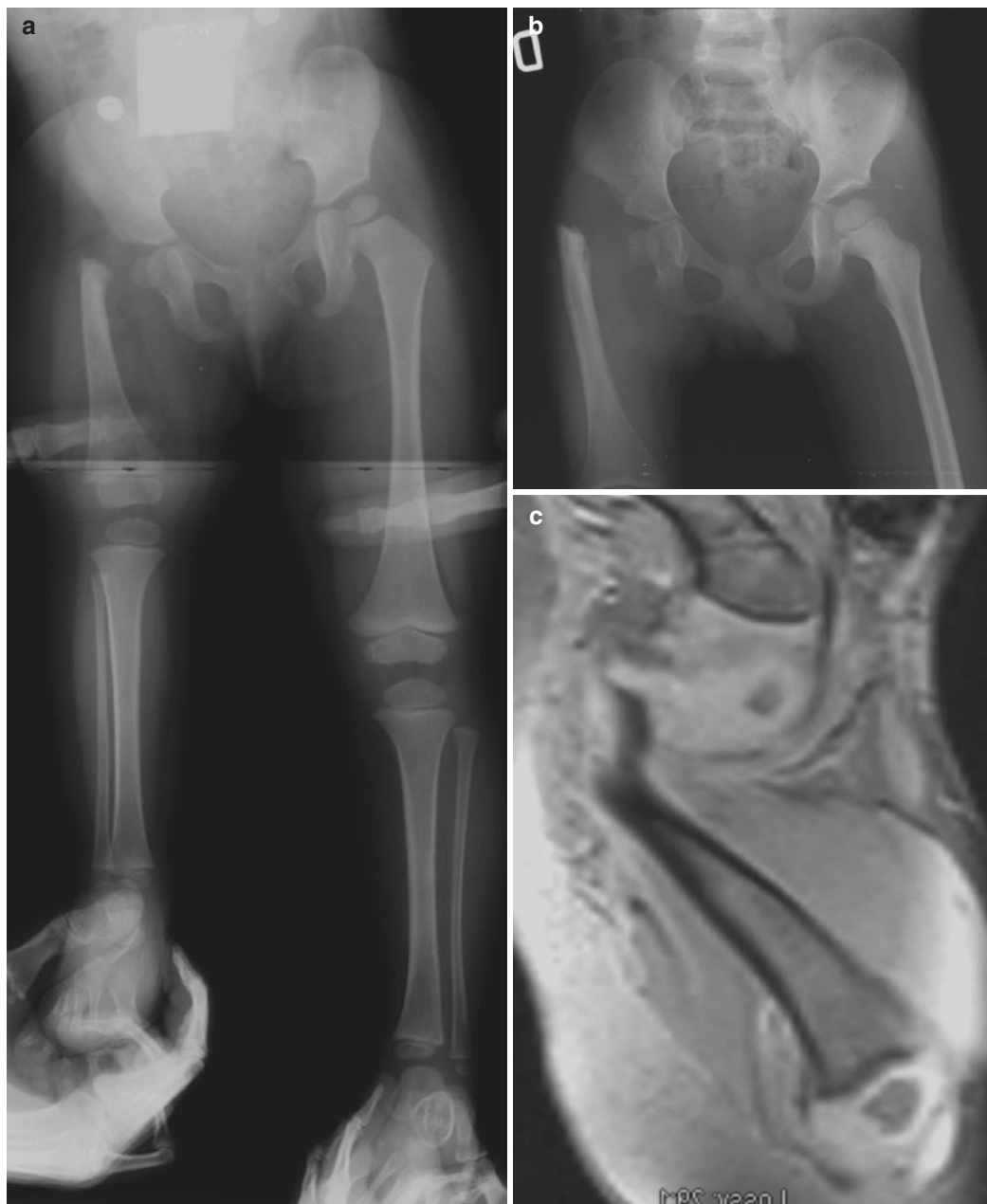


Fig. 35.4 (a) Long anteroposterior (AP) radiograph at age 24 months. Congenital femoral deficiency type 1b neck type. (b) AP pelvis showing lack of ossification of femoral neck. Note that the femur is not migrating proximally or medially indicating that there is some tissue preventing the femoral shaft from moving proximal or medial. (c) MRI showing cartilaginous femoral neck. This is referred to as delayed ossification of the femoral neck. (d) Lateral (*left*) and AP (*right*) radiographs of the femur after the SUPERhip procedure. Note the beginning of early ossification of the femoral neck in the superior neck region where the bone morphogenetic protein was placed. (e) The femoral neck is ossified and there is obvious growth of the distal femoral

physis away from the distal end of the plate. (f) Standing radiograph a year after the SUPERhip procedure. (g) external fixator in place during lengthening of 8 cm of the femur. The external fixator extends to the knee with a hinge. (h) After 8 cm lengthening the external fixator was removed and the femur rodded to prevent fracture. (i) Erect leg radiograph during the second lengthening, using Precice Lengthening Nail (Nuvasive Specialized Orthopedics, Irving CA, USA). Hemiepiphyseodesis plate in place to treat the genu valgum. (j) Erect leg radiograph (*right*) and long lateral radiograph (*left*) after completion of lengthening with Precice nail and after screw epiphyseodesis of left distal femur

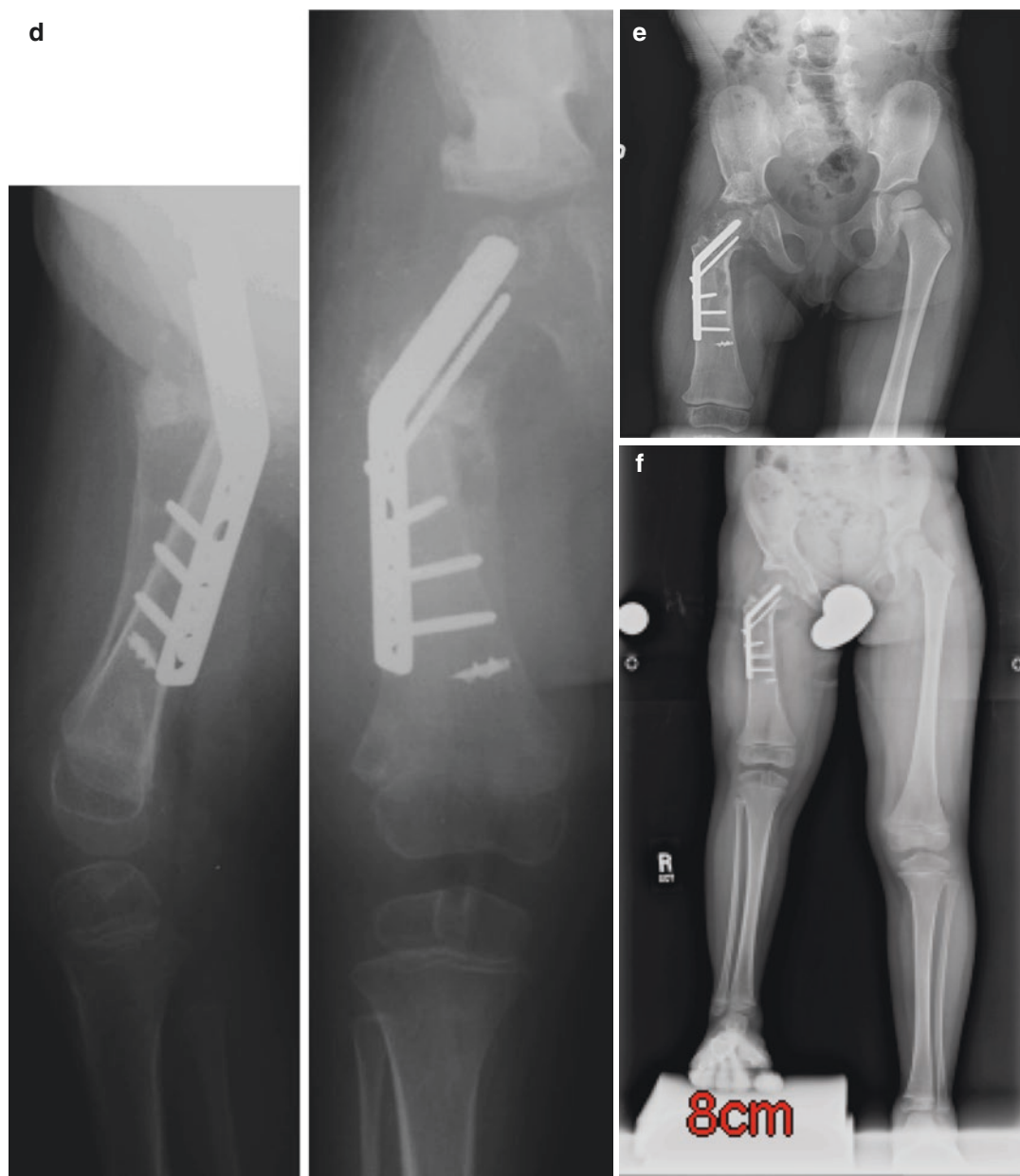


Fig. 35.4 (continued)

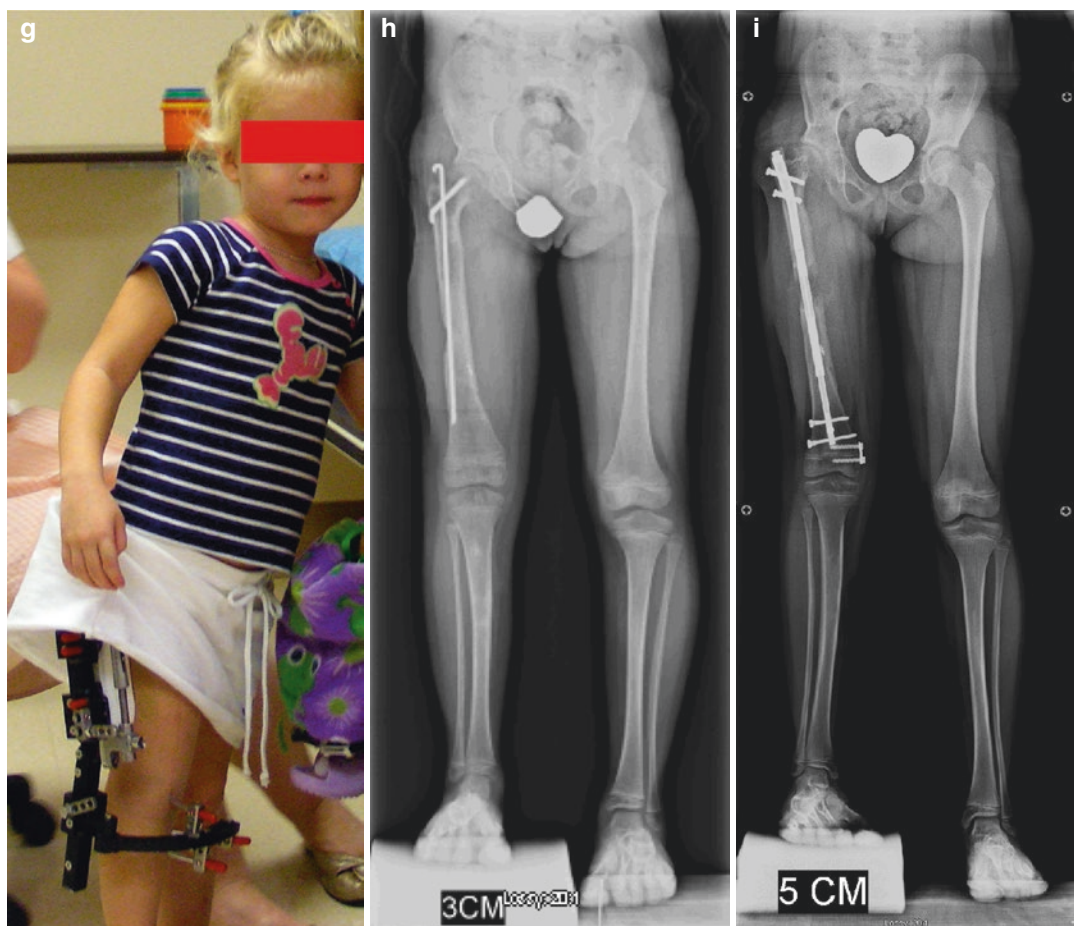


Fig. 35.4 (continued)

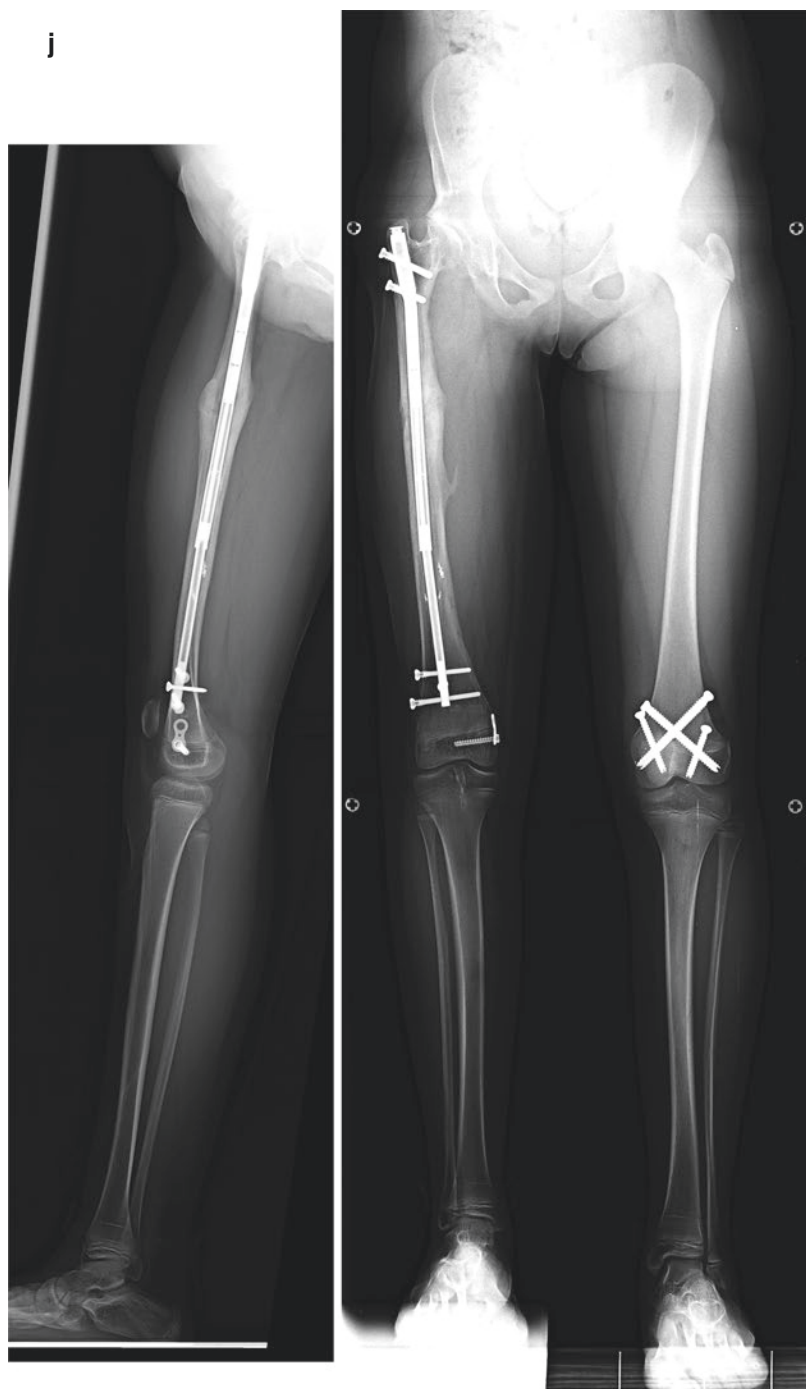


Fig. 35.4 (continued)

radiographs are taken supine with both feet pulled down by a parent to keep the hip and knee in maximum extension (see Figs. 35.4a and 35.5a). The x-ray should include the pelvis, both femurs and both tibias and feet. This x-ray is used to measure the length discrepancy between the femurs and tibias. Total leg length discrepancy including the foot can be measured from a standing x-ray by measuring from the top of the hip joints. A simulated standing lateral radiograph of both feet can also be taken to directly measure the foot height differences. The sum of femur, tibia and foot height difference gives the total LLD. A long lateral radiograph of the femur and tibia with the knee in maximum extension is also used to evaluate for knee flexion deformity (see Figs. 35.3a, 35.5a, and 35.6b). A supine AP pelvis radiograph (see Figs. 35.3b and 35.6a) is used to study acetabular dysplasia and ossification of the femoral neck.

Magnetic resonance imaging is useful if there is delayed ossification of the femoral neck (see Fig. 35.4c) or subtrochanteric region (see Fig. 35.5b). It can help determine whether a cartilagenous femoral neck is present or not distinguishing between a delayed ossification of the femoral neck (type 1b) vs a true pseudarthrosis of the femoral neck (type 2).

Goals of Treatment

1. Correct femur/hip deficiency, deformity and dysplasia
2. Make the hip stable
3. Serial lengthenings of femur to equalize limb length discrepancy.

One cannot equalize the limb length discrepancy in the presence of significant femoral deformity or hip dysplasia. Therefore surgery to correct the upper femoral deformity and to secure hip stability is preparatory to femoral lengthening and must be performed prior to beginning with a lengthening program.

Treatment Strategies

Paley type 1a:

- (a) extra-articular release of contractures by lengthening the tethering soft tissues without weakening these muscles
- (b) subtrochanteric corrective osteotomy with shortening to acutely correct all of the bony deformities so that the normal anatomy of the femur is restored
- (c) treat acetabular dysplasia

Paley type 1b neck type hip surgery:

- (a) Extra-articular release of contractures by lengthening the tethering soft tissues without weakening these muscles
- (b) Subtrochanteric corrective osteotomy with shortening to acutely correct all of the bony deformities so that the normal anatomy of the femur is restored
- (c) Cause the delayed ossification of the femoral neck to ossify
- (d) Treat acetabular dysplasia

Paley type 1b subtrochanteric type hip surgery:

- (a) Extra-articular release of contractures by lengthening the tethering soft tissues without weakening these muscles
- (b) Subtrochanteric corrective osteotomy with shortening to acutely correct all of the bony deformities so that the normal anatomy of the femur is restored
- (c) Resect the region of delayed ossification of the subtrochanteric femur
- (d) Treat acetabular dysplasia

Paley type 2a hip surgery:

- (a) Extra-articular release of contractures by lengthening the tethering soft tissues without weakening these muscles

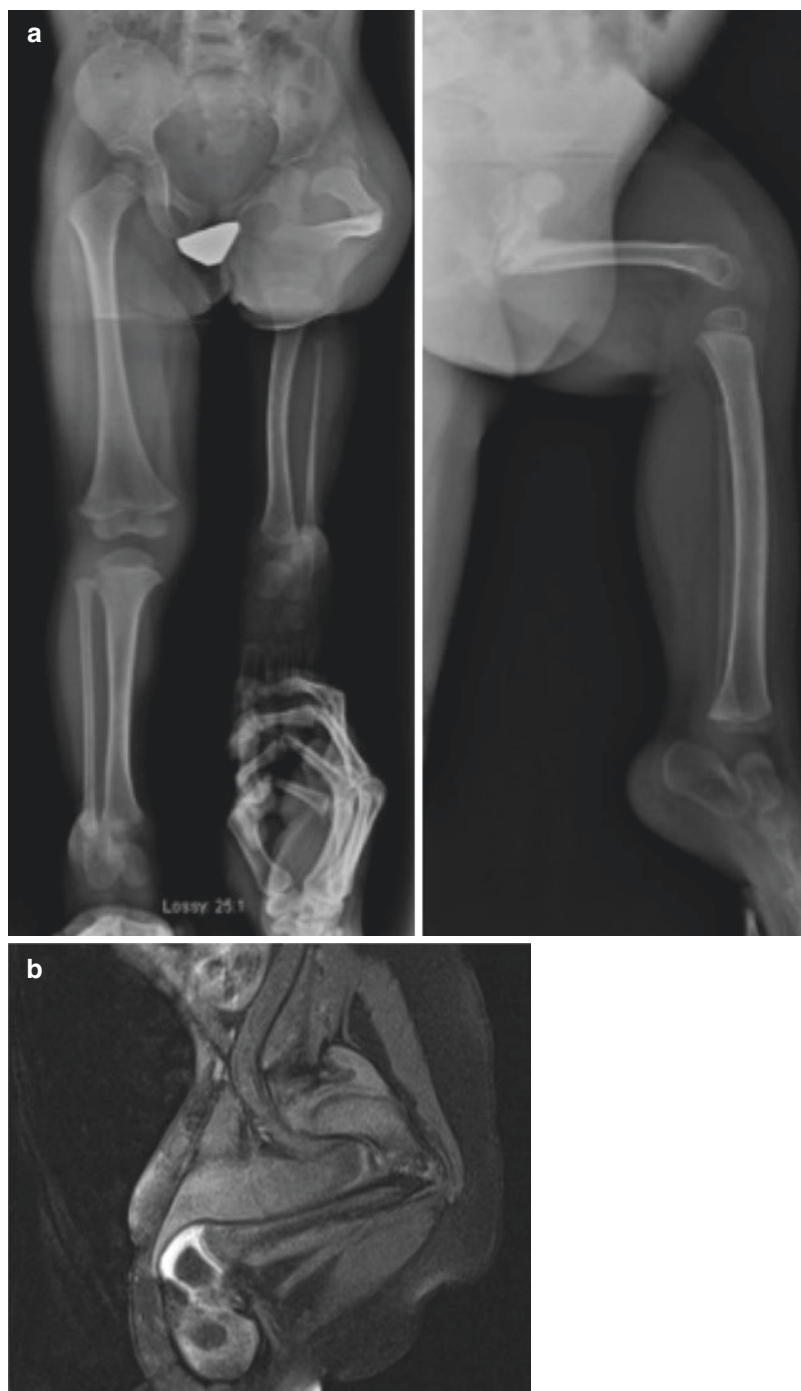

Fig. 35.5 (a) Long anteroposterior (AP) pull down radiograph showing severe bend in left subtrochanteric region of femur (*right*) and long lateral radiograph in maximum extension showing severe knee flexion contracture. This is a type 1b congenital femoral deficiency, subtrochanteric type. (b) Magnetic resonance image showing the greater than 90° bend in the femur and the region of delayed ossification in the subtrochanteric region. (c) Erect

leg radiograph after SUPERhip procedure with posterior knee capsulotomy. There has been significant growth stimulation (the distal end of the femoral plate was next to the distal physis after surgery) The knee comes into full extension and flexes 90°. (d) AP femur radiograph during lengthening with external fixator in place. (e) Erect legs radiograph after lengthening. The rodding was done to prevent fracture

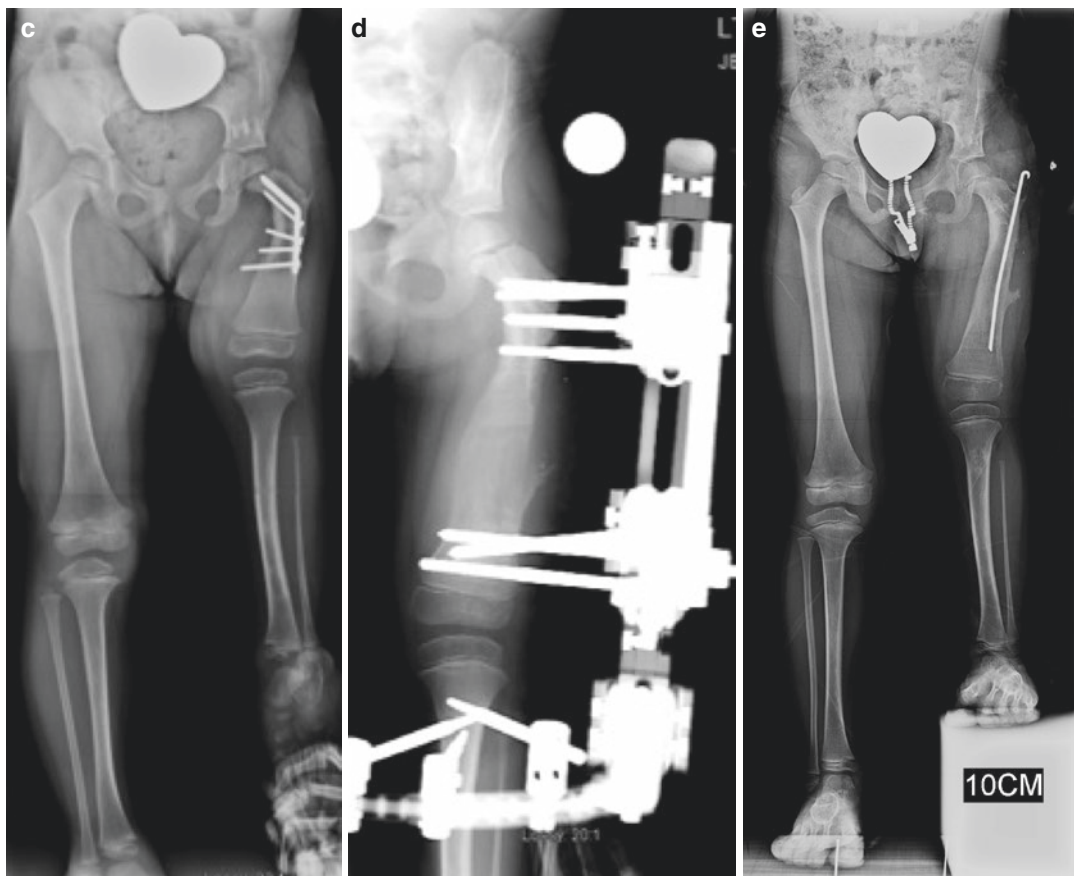


Fig. 35.5 (continued)

- (b) Reconstruct femoral neck
- (c) Unite new femoral neck to mobile femoral head

Paley type 2b hip surgery:

- (a) Extra-articular release of contractures by lengthening the tethering soft tissues without weakening these muscles
- (b) Reconstruct femoral neck
- (c) Separate femoral head fusion from acetabulum and make the femoral head mobile
- (d) Unite new femoral neck to mobile femoral head

Paley types 1a and 1b lengthening surgery:

- (a) Lengthen through distal femoral osteotomy
- (b) Apply external fixator to femur articulated to the tibia with a knee locking bar
- (c) Extend the external fixator to the pelvis with a hip hinge only if hip stability or femoral neck integrity are suspect

Paley types 2 lengthening surgery:

- (a) Lengthen through distal femoral osteotomy
- (b) Apply external fixator to femur articulated to tibia and articulated to pelvis for knee and hip motion respectively

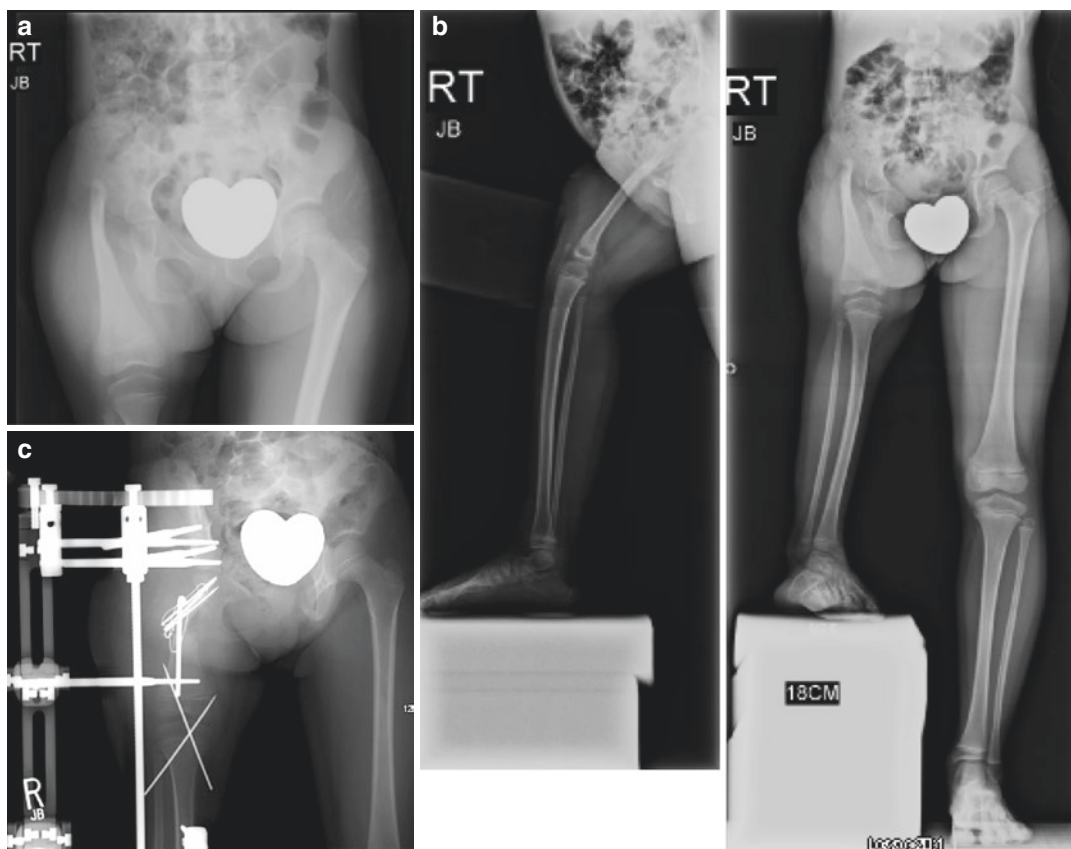


Fig. 35.6 (a) Anteroposterior pelvis radiograph showing high riding femur. The ossific nucleus of the femoral head is also clearly visible. (b) Erect leg radiograph showing the LLD (*right*). The knee has a mild flexion deformity (*left*). (c) After SUPERhip2 procedure with neutralizing external fixator in place. (d) Final radiograph before

lengthening. There has been a lot of growth stimulation. (e) Erect leg radiograph during 8 cm lengthening of right femur. The external fixator is seen in place. (f) Radiographs showing the bone is healed and a rod is in place to prevent from fracture

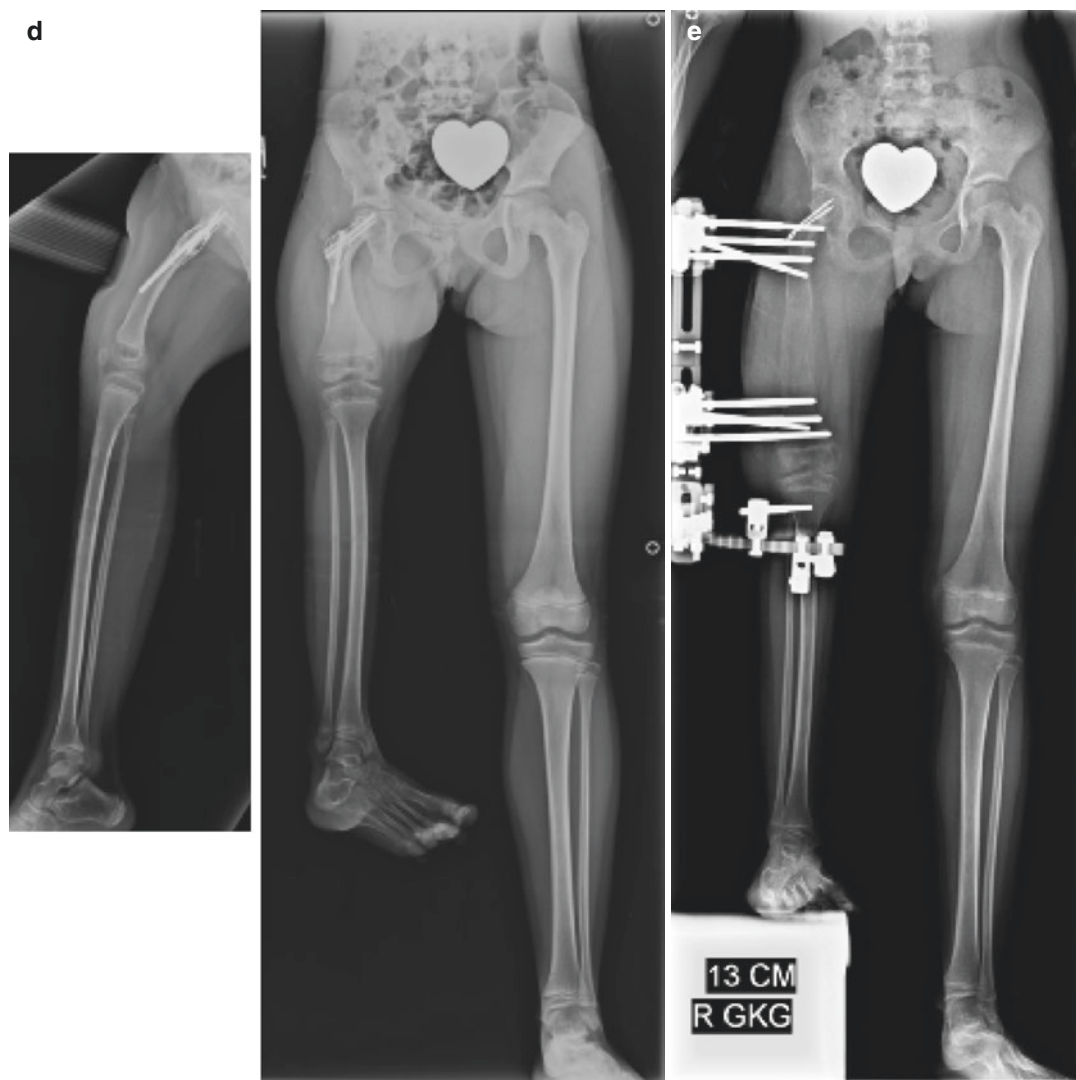


Fig. 35.6 (continued)

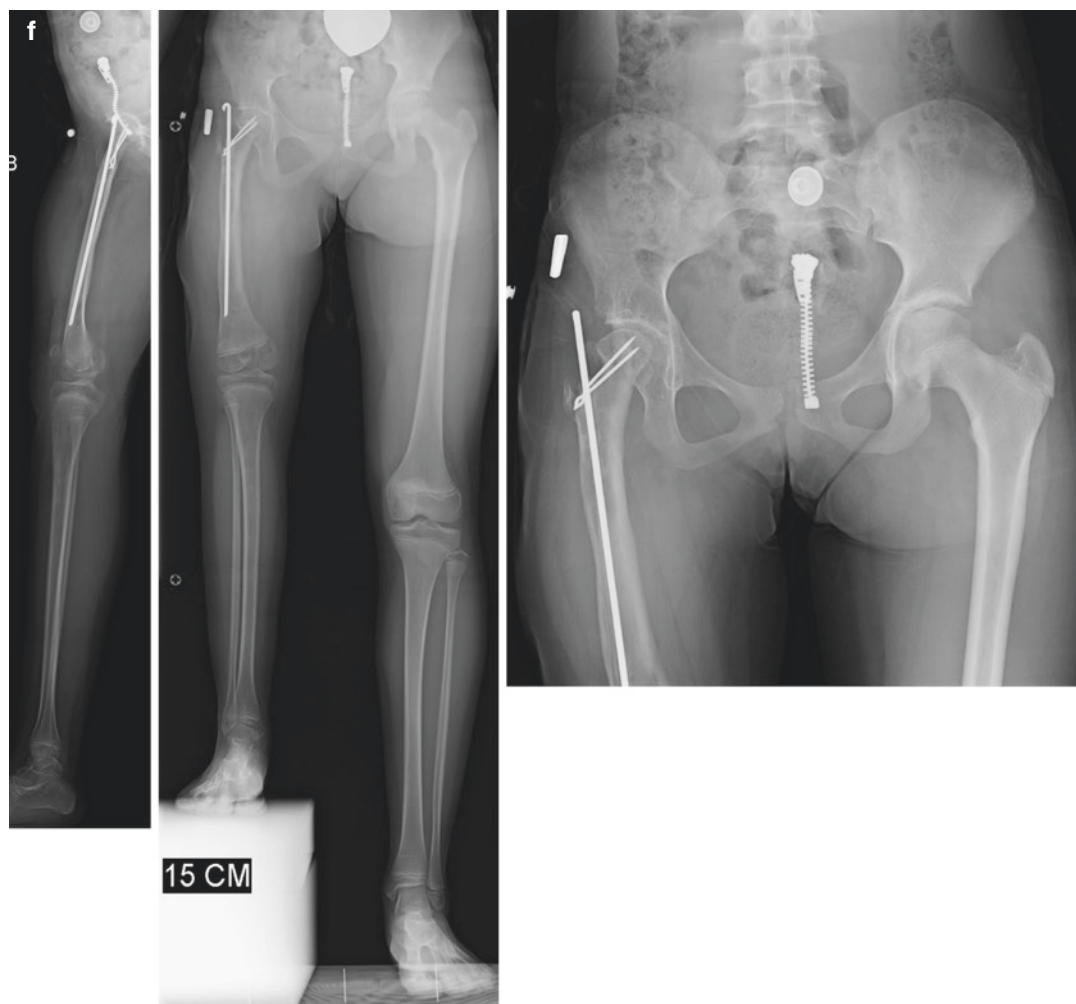


Fig. 35.6 (continued)

Surgical Details

SUPERhip Surgical Technique [2, 4–8] (Figs. 35.7, 35.8, and 35.9)

1. *Positioning, prepping and draping* (see Fig. 35.7a, b). An epidural is placed by the anesthesia service with a catheter running up the back on the non-operative side. A Foley catheter is placed and also routed to the non-operative side. The patient should be moved to the edge and foot of the radiolucent table in a supine position. The ipsilateral arm should be appropriately padded and placed across the patient's chest. A radiolucent bump (usually a folded towel or sheet) is placed beneath the ipsilateral ischium to roll the pelvis 45° towards the opposite side. The bump should not be beneath the iliac crest or lower back. The entire side should be prepped and draped free from the nipple to the toes. The drapes should extend from the mid buttocks to the scrotal/labial-thigh fold. The lower limb should be completely free of the drapes.

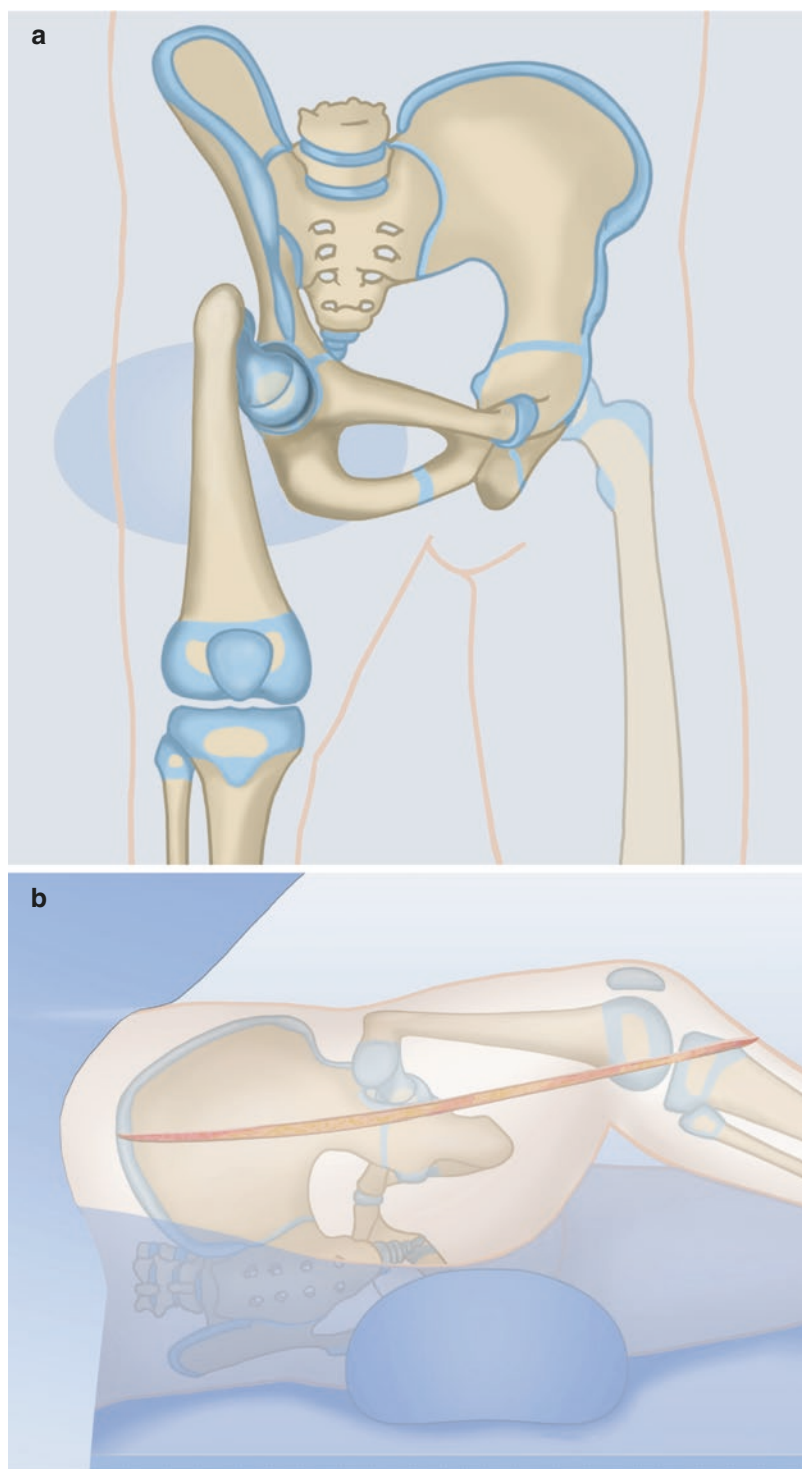


Fig. 35.7 (a–j) Illustrations of SUPERhip procedure soft tissue releases: see steps of surgery corresponding to each figure. (© 2014 The Paley Foundation, with permission. All rights reserved)

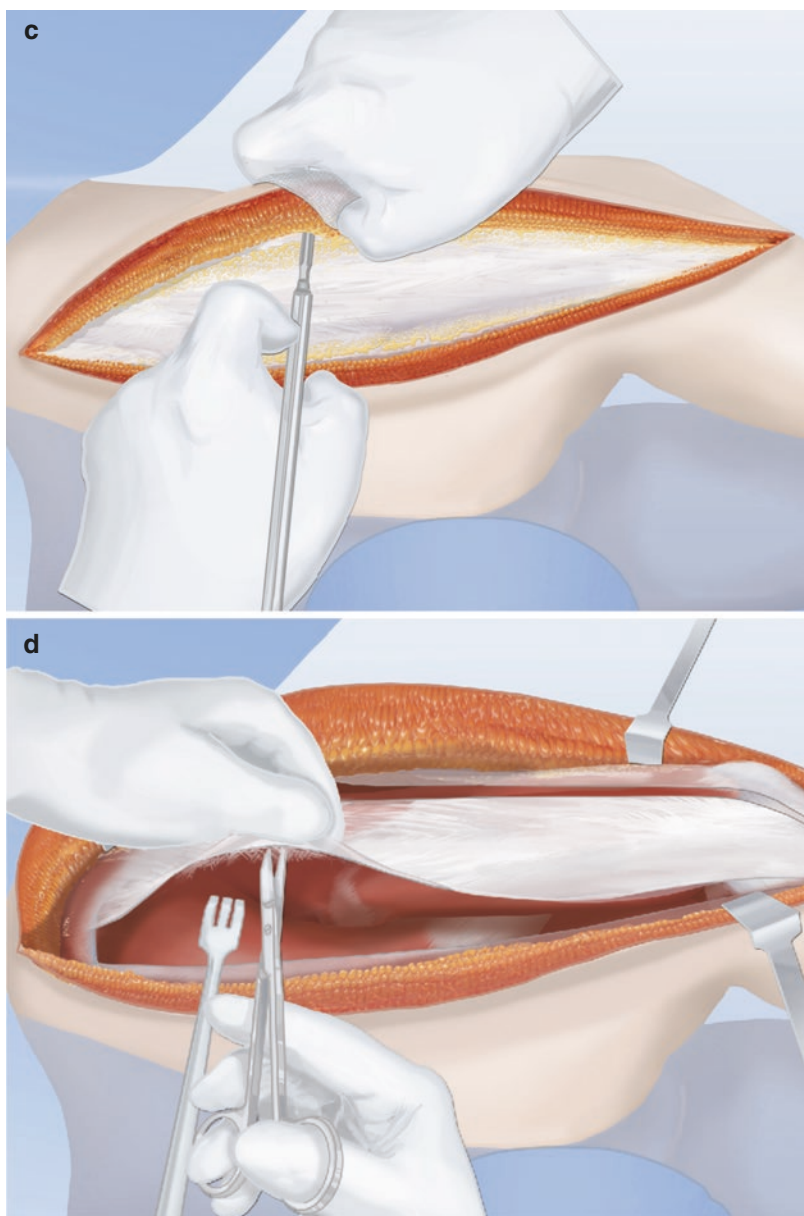


Fig. 35.7 (continued)

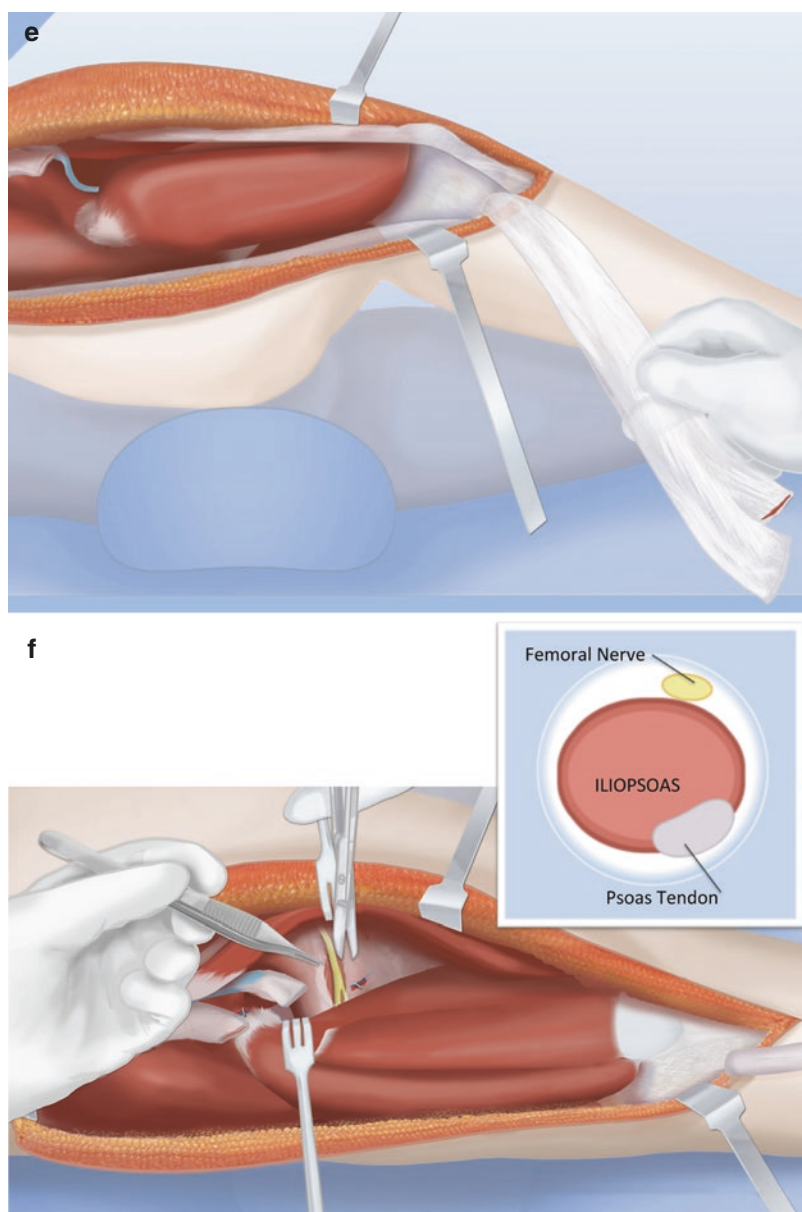


Fig. 35.7 (continued)

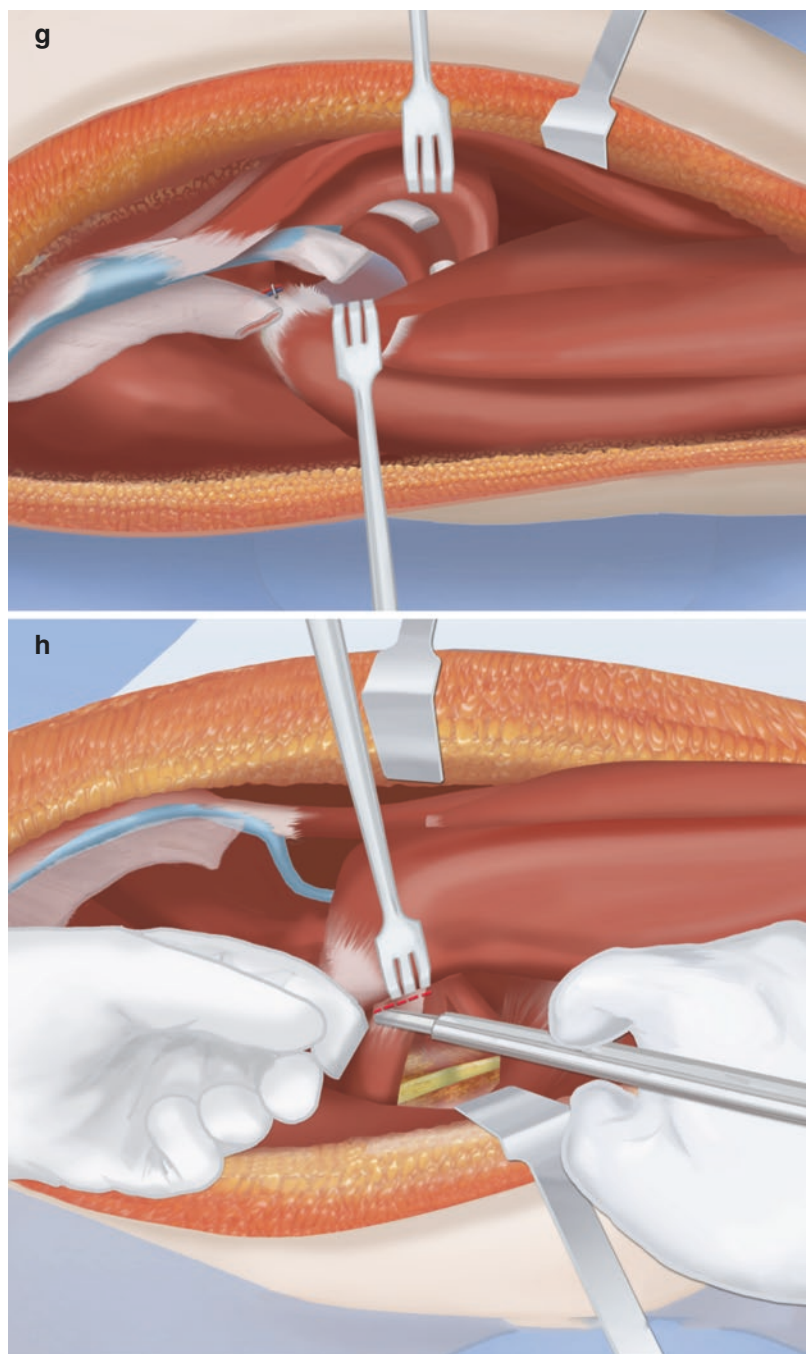


Fig. 35.7 (continued)

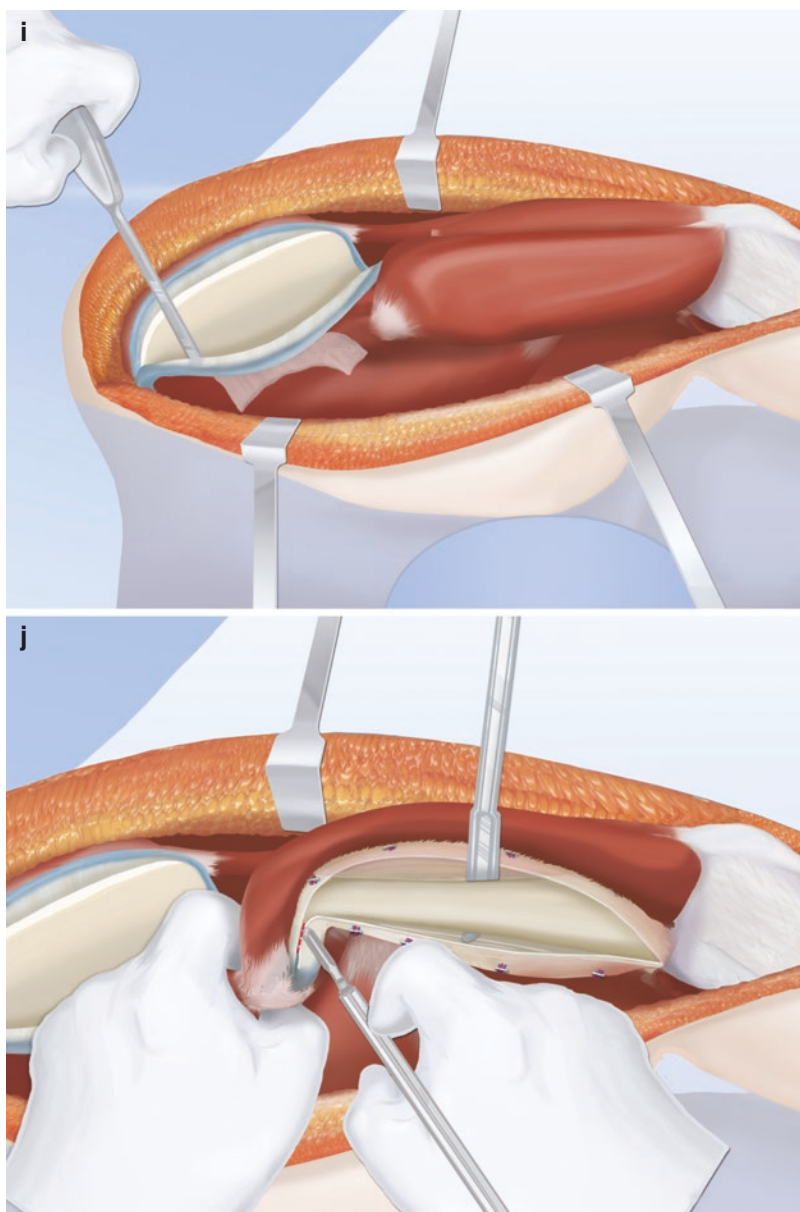


Fig. 35.7 (continued)

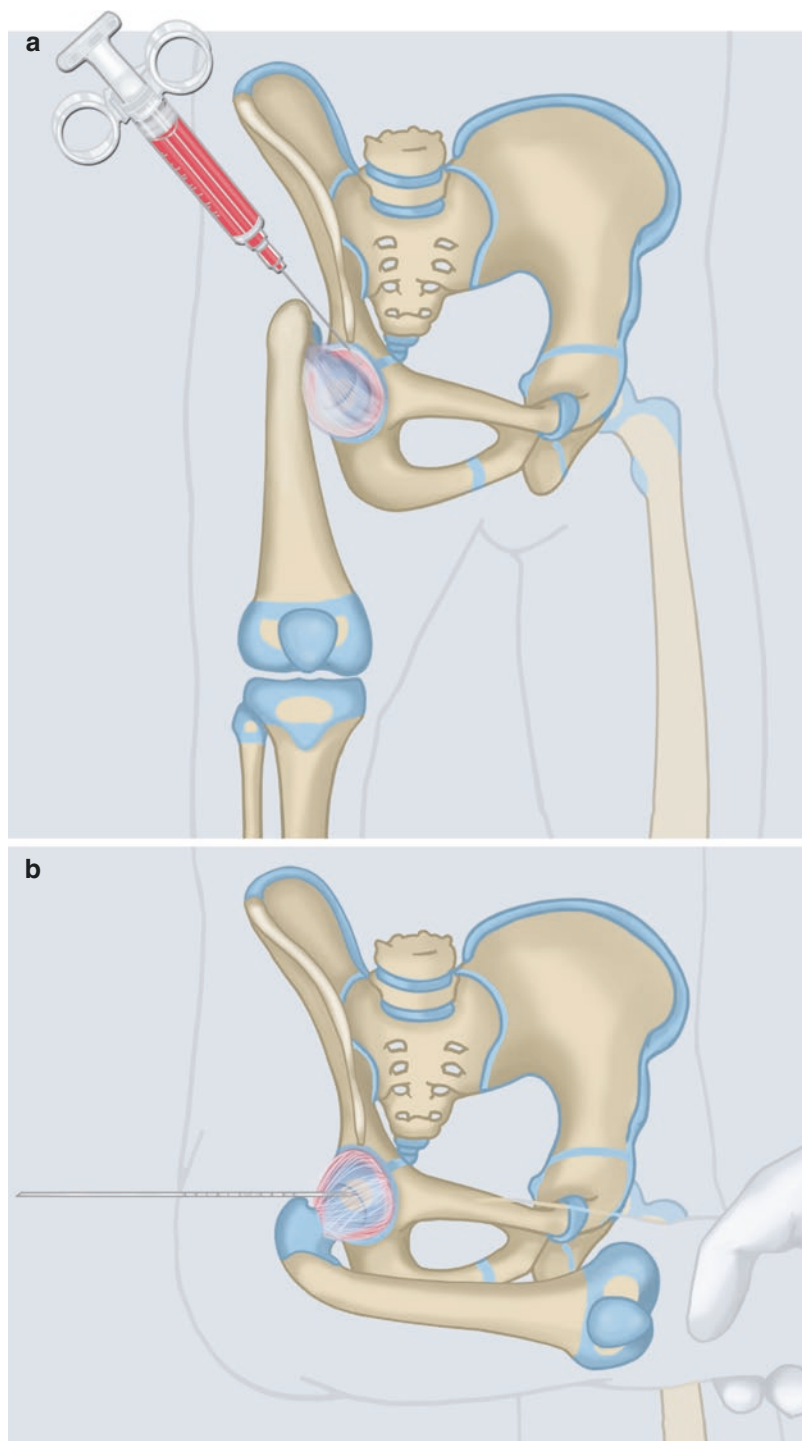


Fig. 35.8 (a–y) SUPERhip bony procedures: see steps of surgery corresponding to each figure. (© 2014 The Paley Foundation, with permission. All rights reserved)

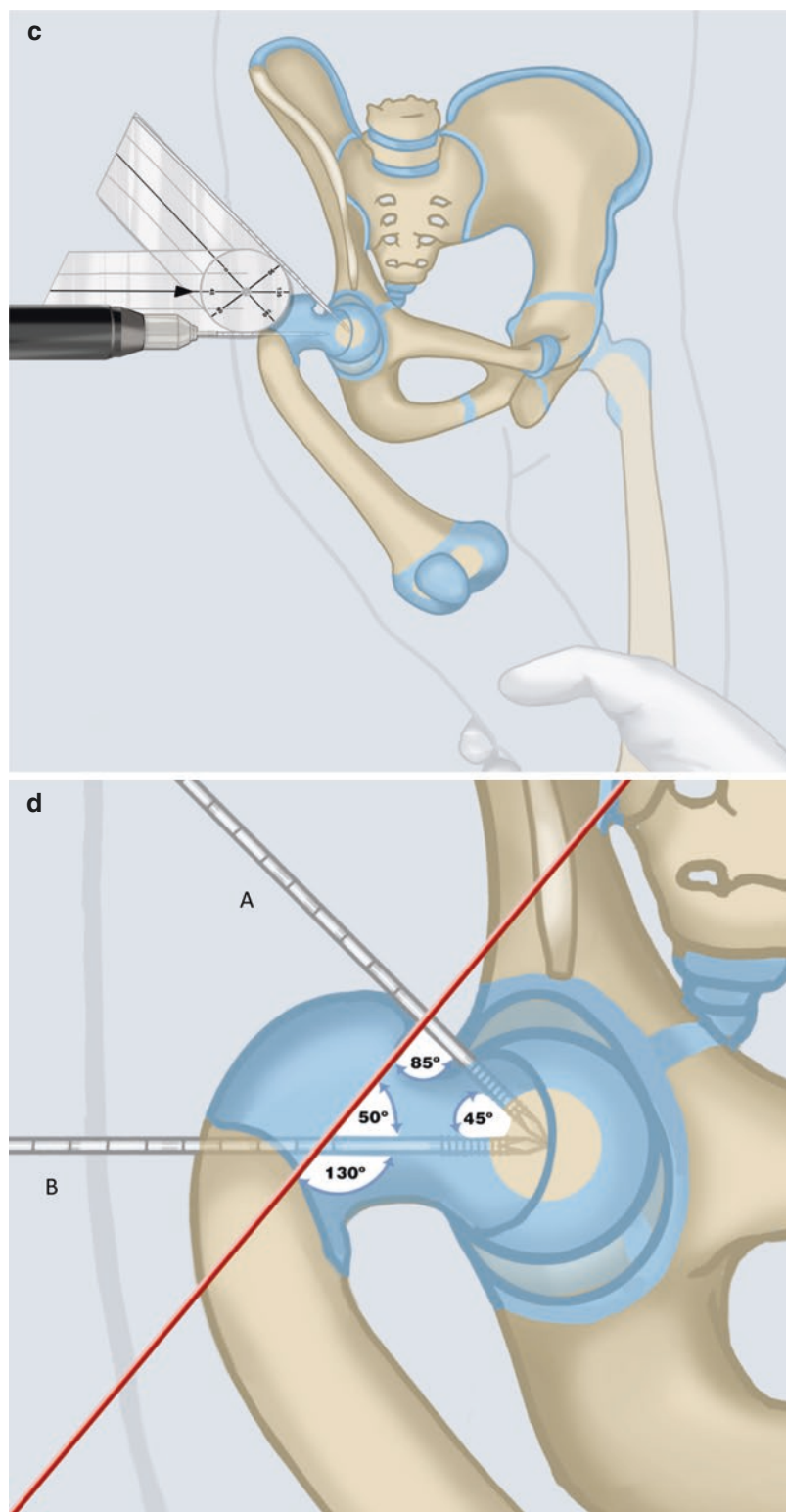


Fig. 35.8 (continued)

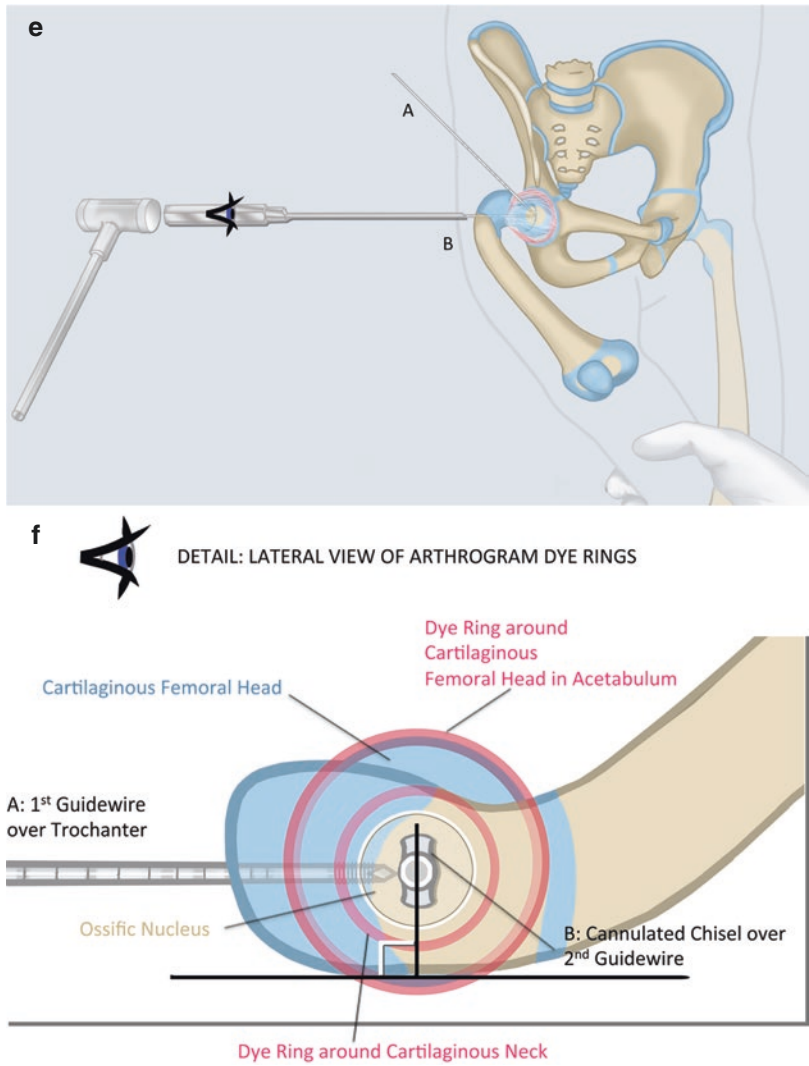


Fig. 35.8 (continued)

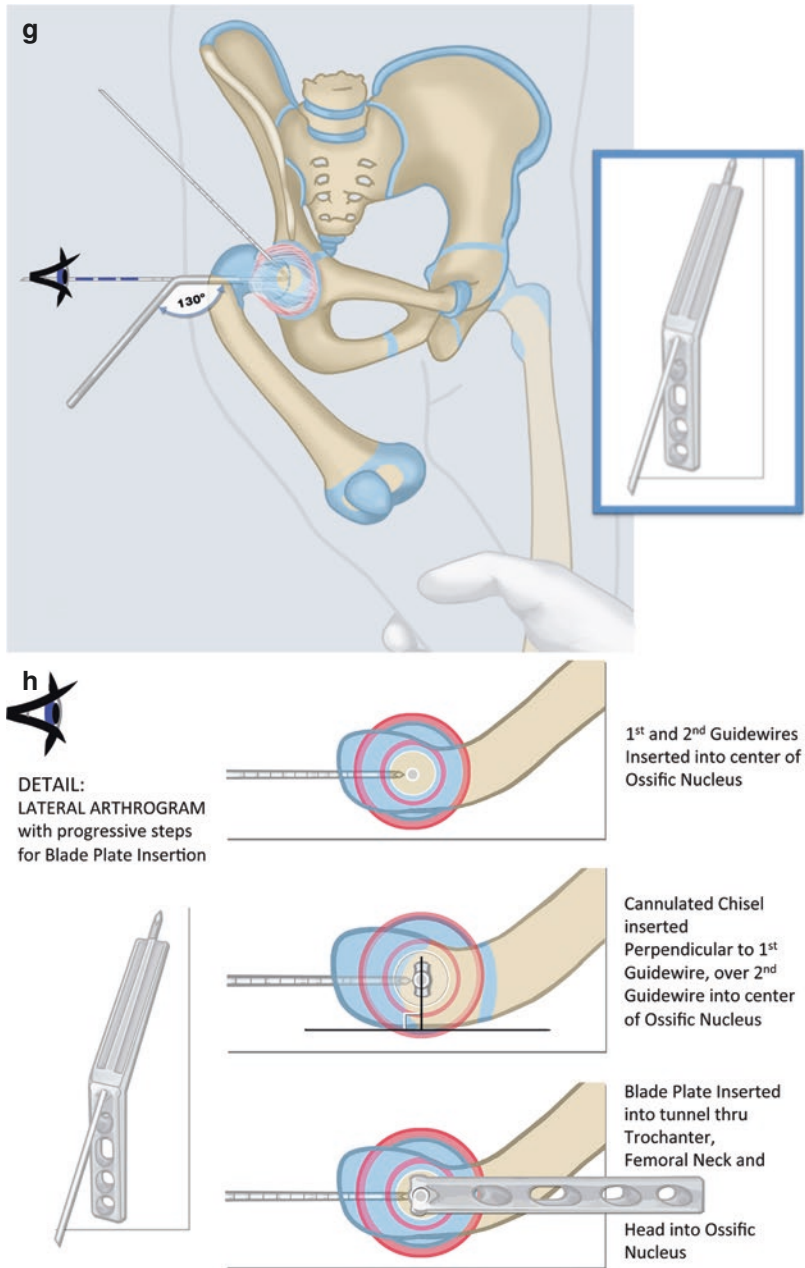


Fig. 35.8 (continued)

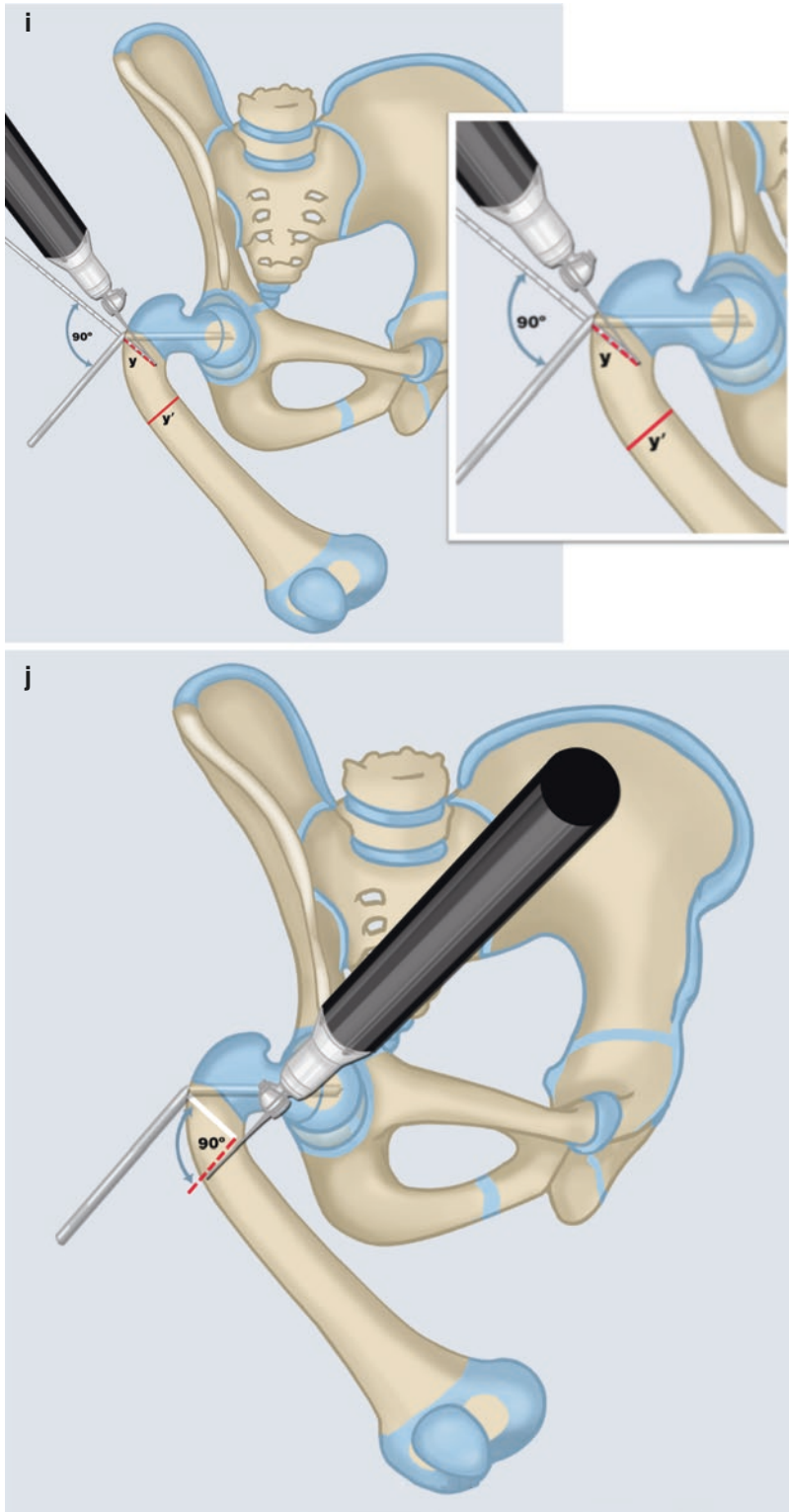


Fig. 35.8 (continued)

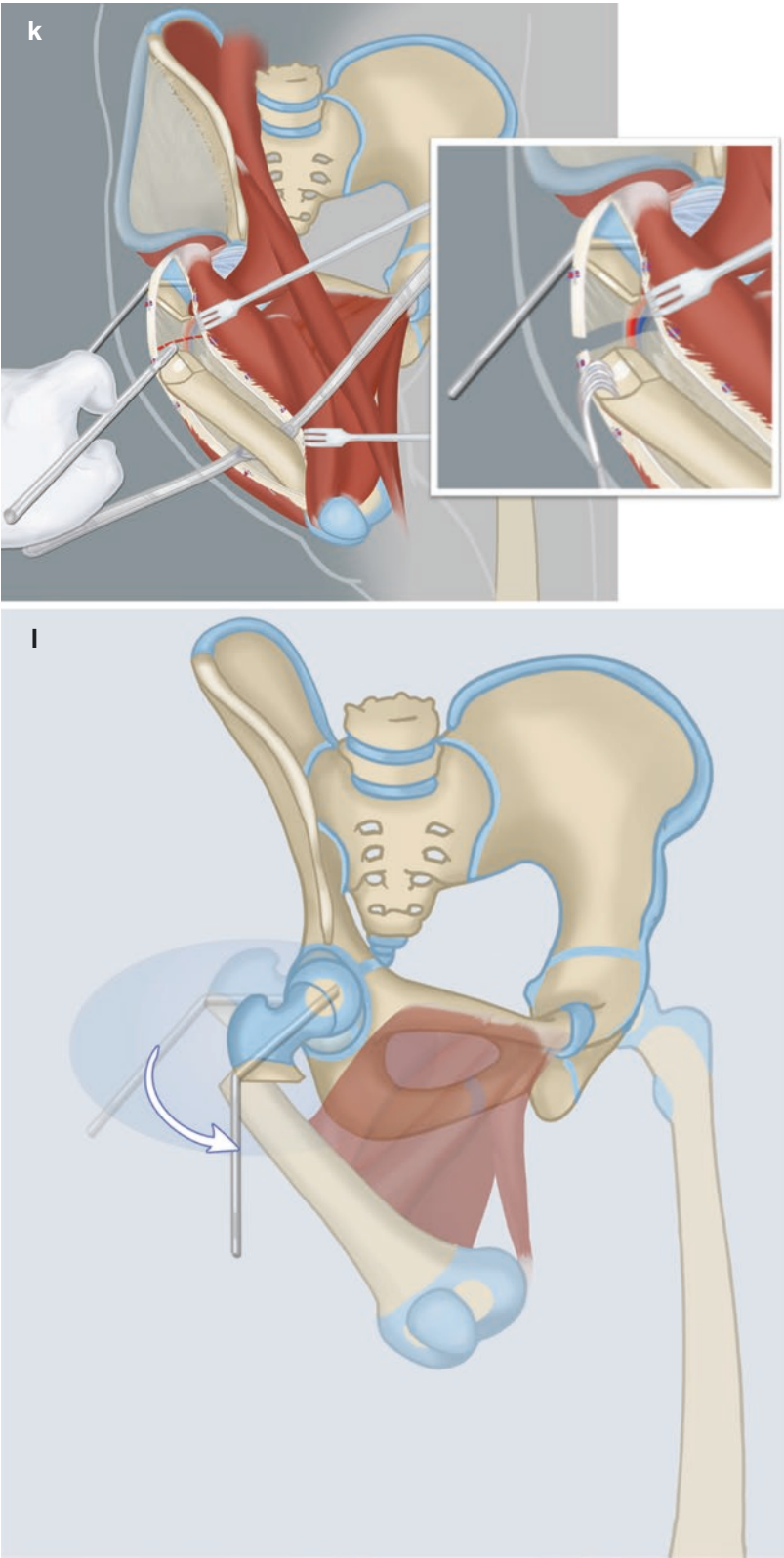


Fig. 35.8 (continued)

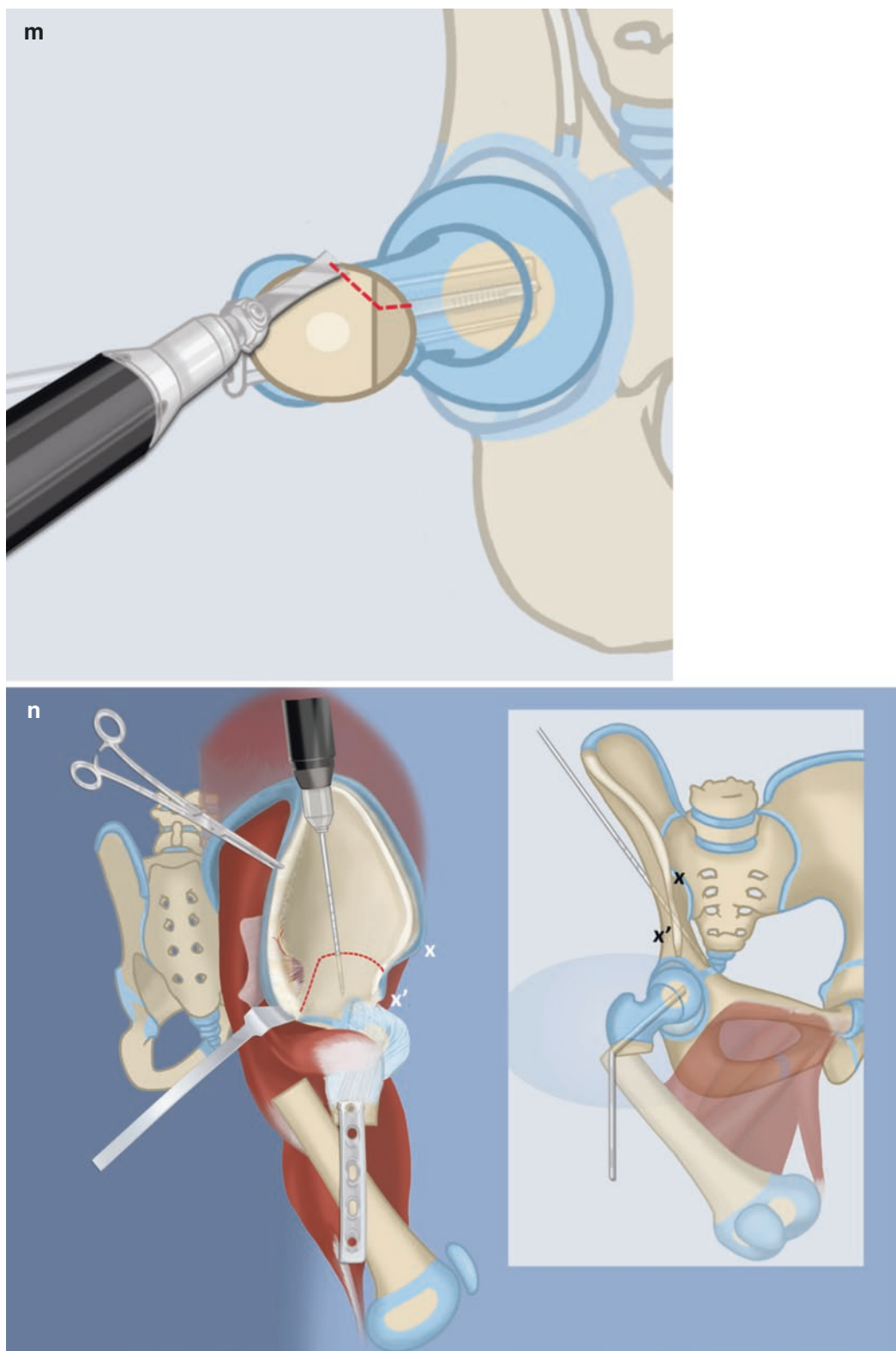


Fig. 35.8 (continued)

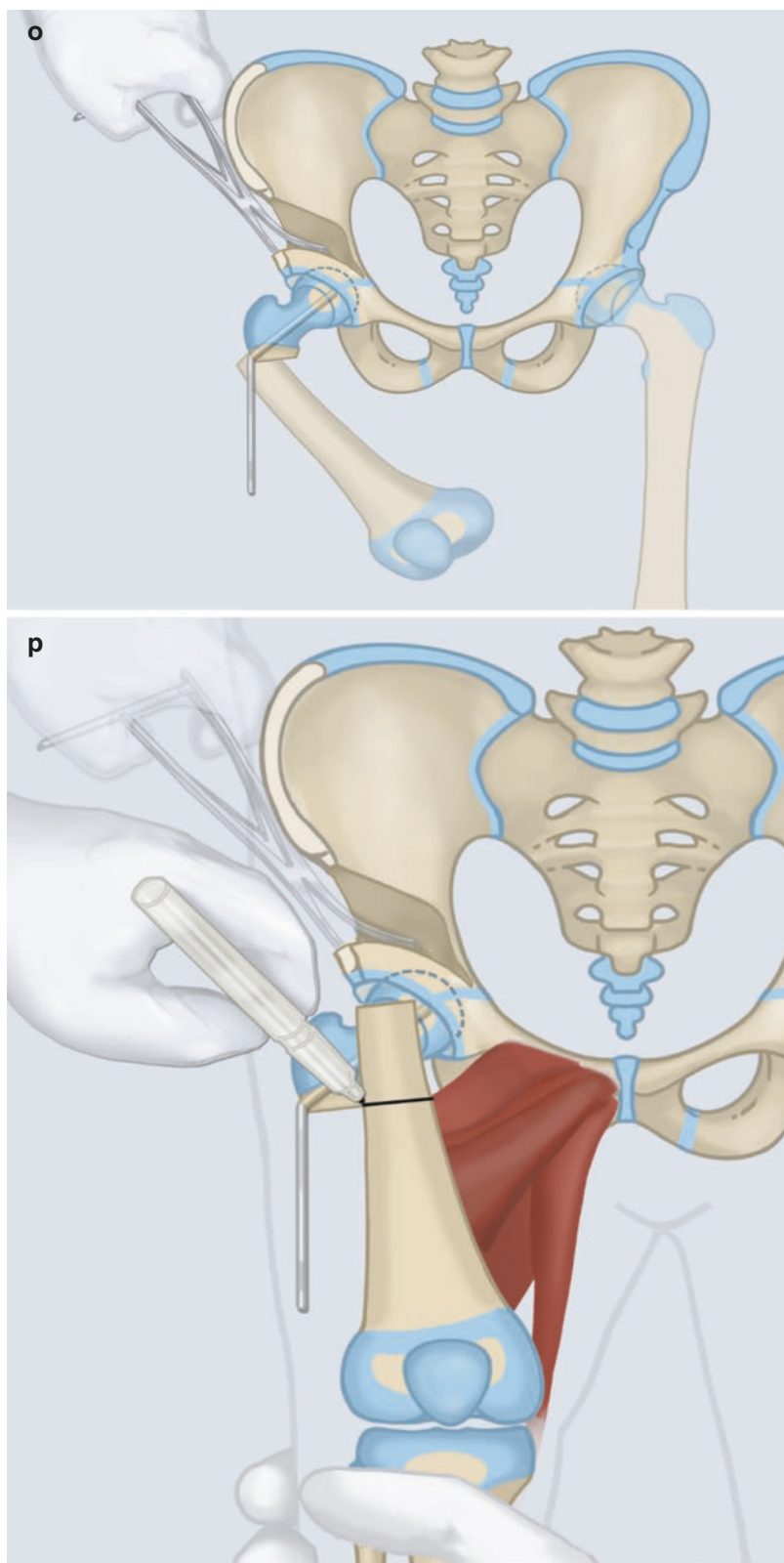


Fig. 35.8 (continued)

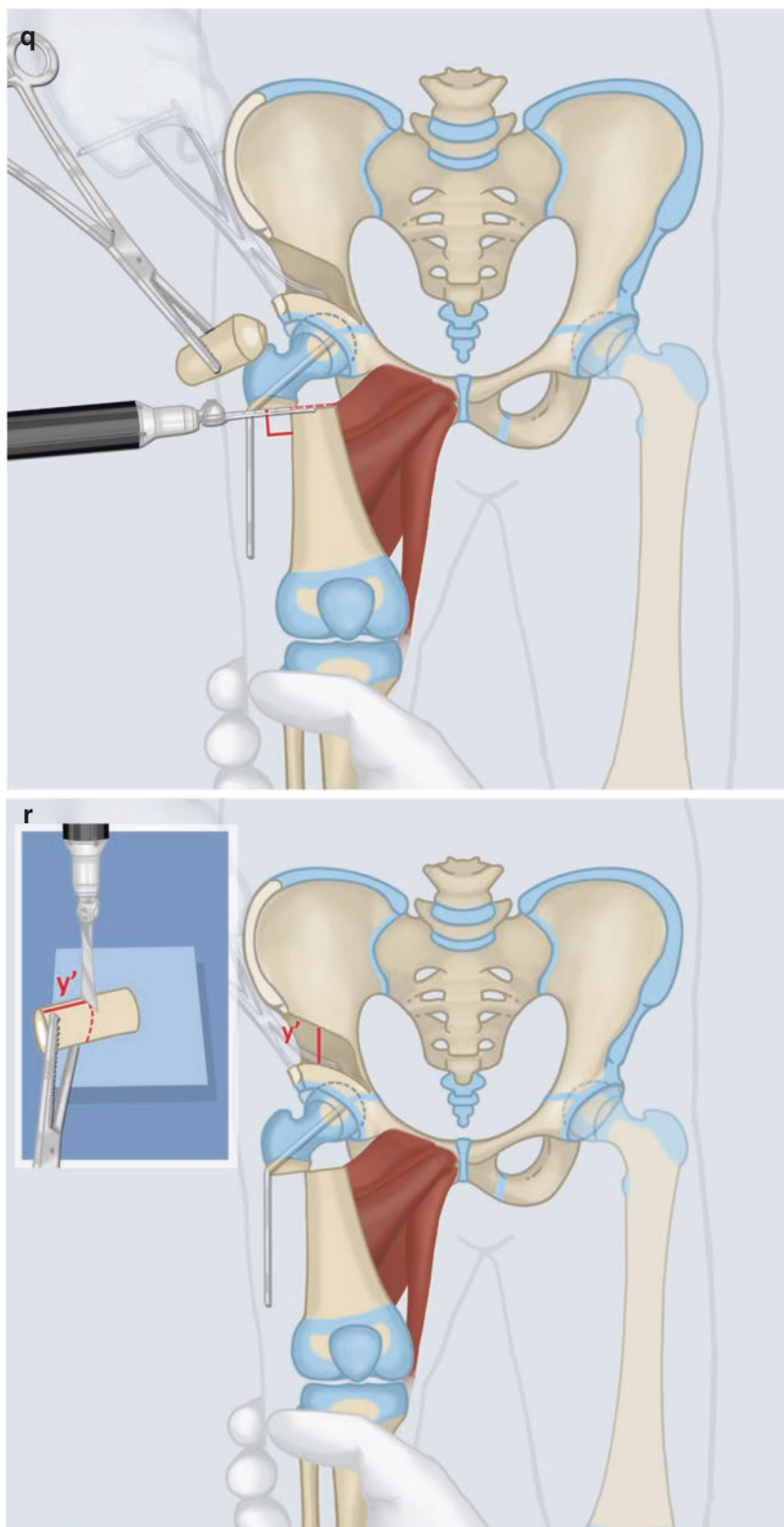


Fig. 35.8 (continued)

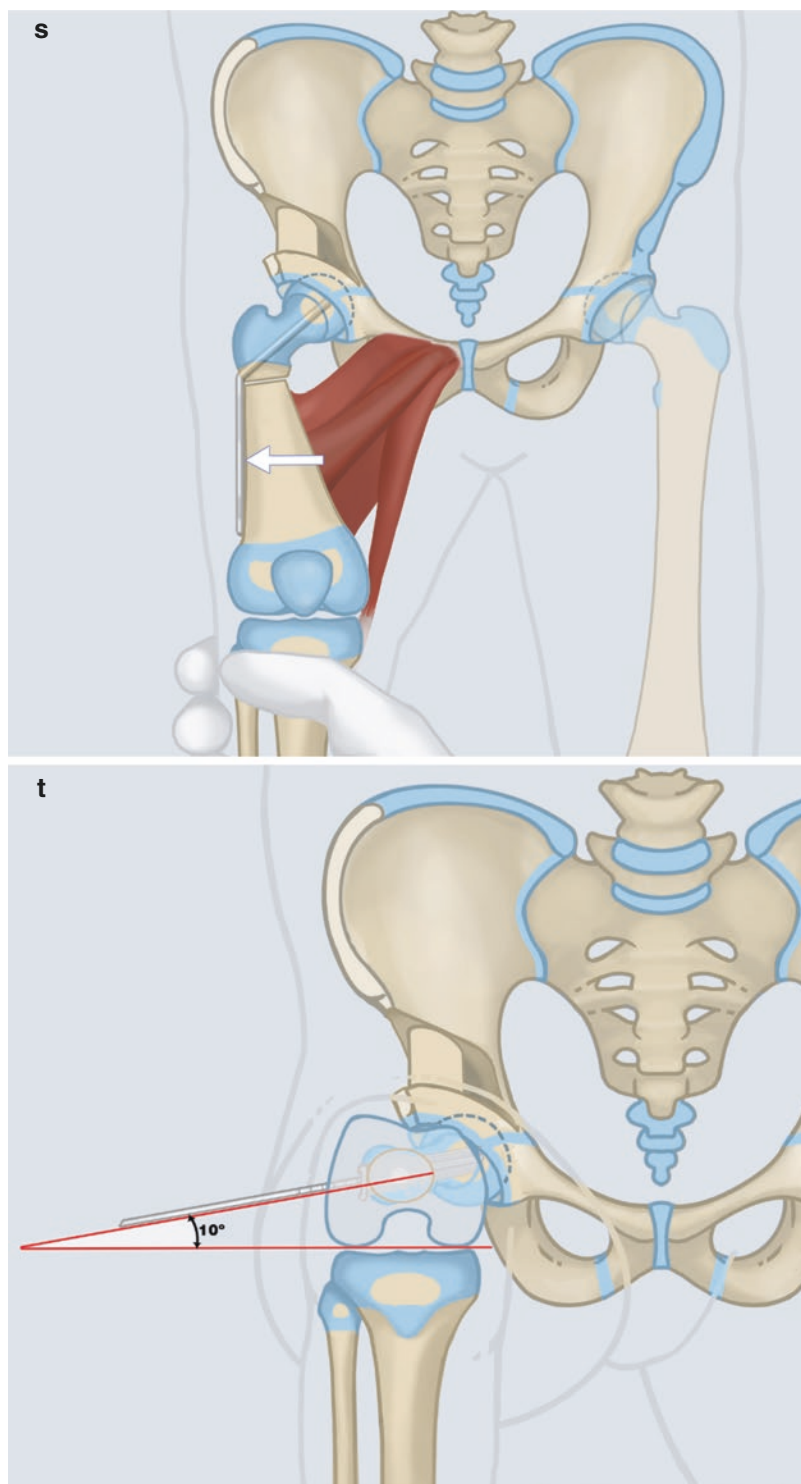


Fig. 35.8 (continued)

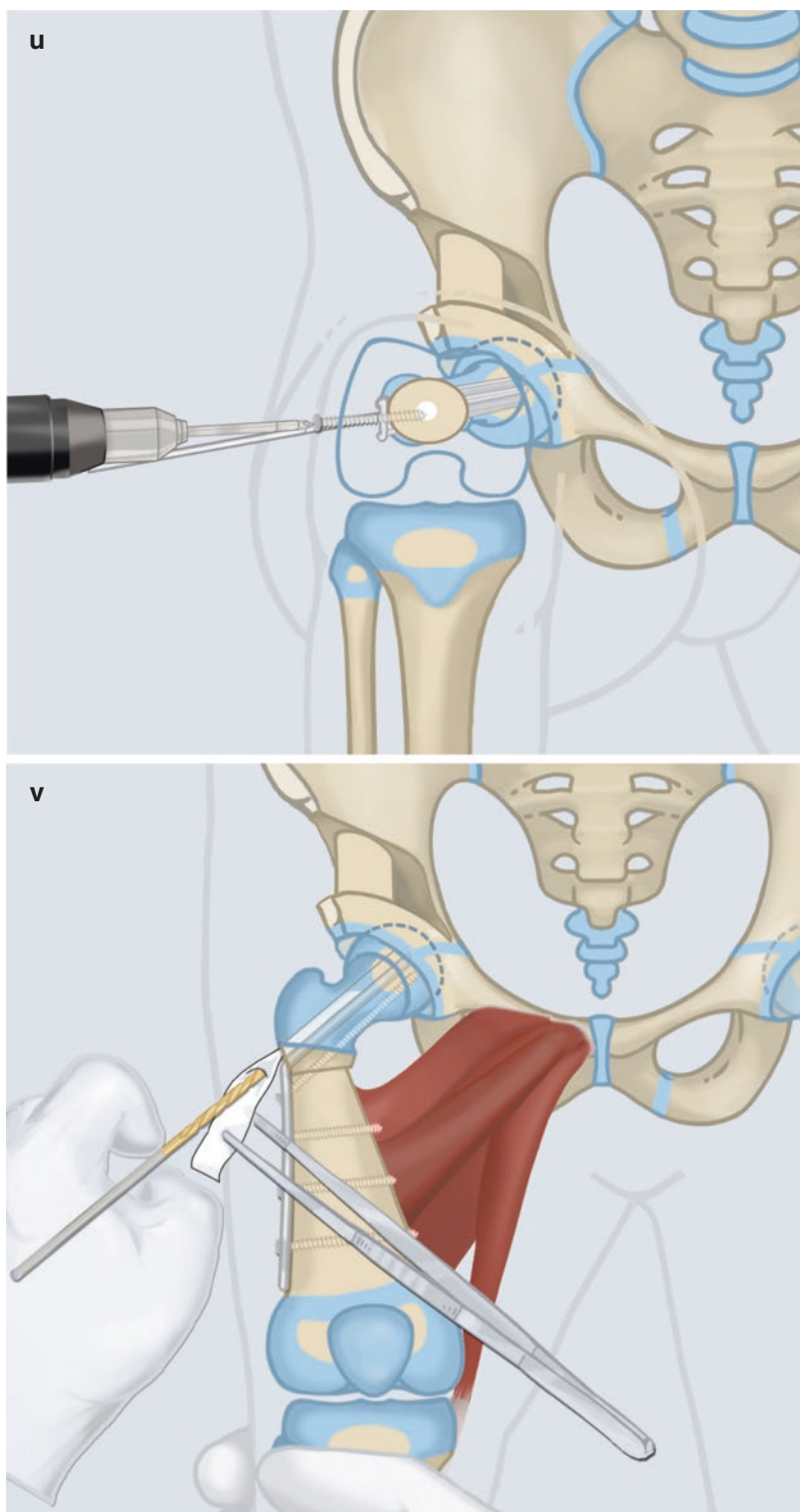


Fig. 35.8 (continued)

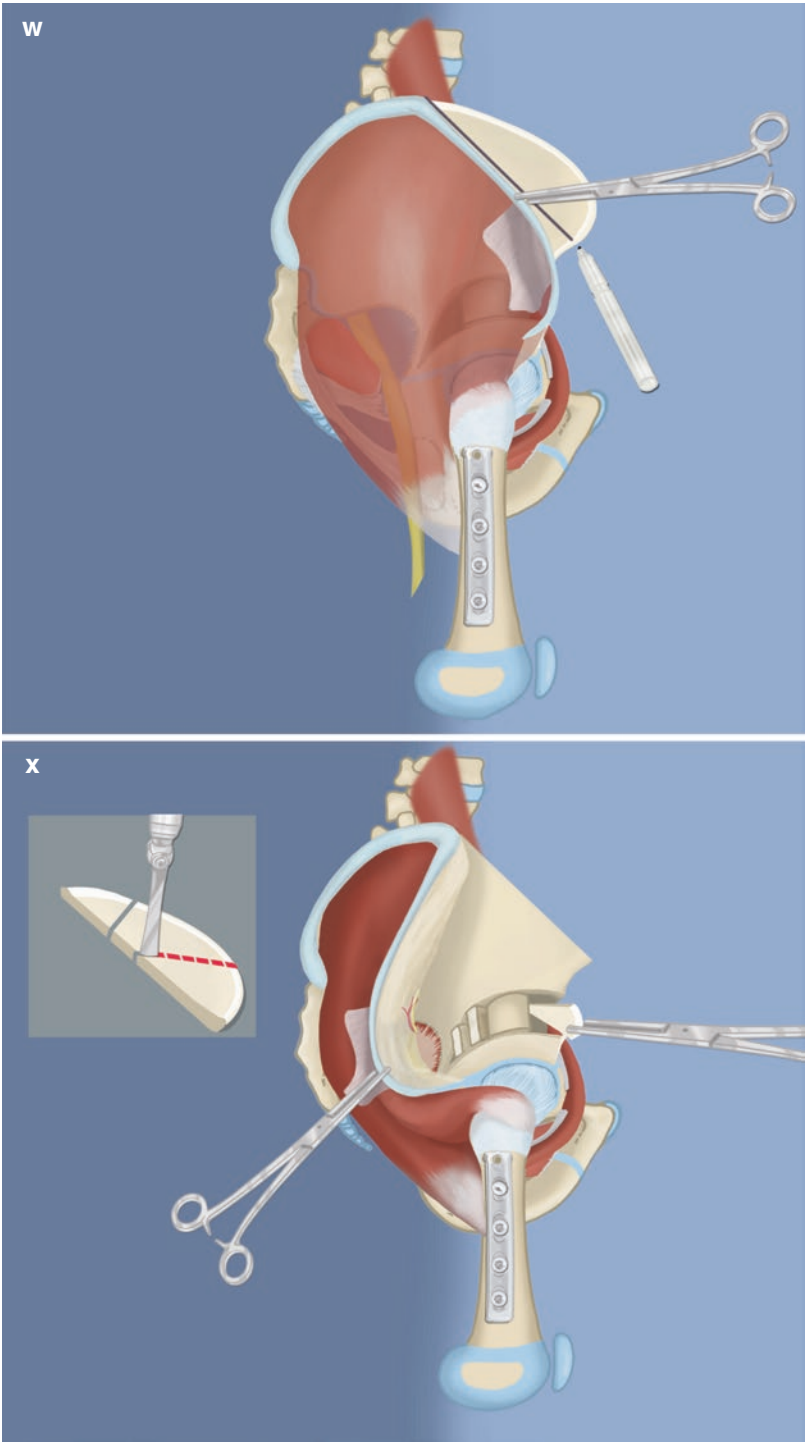


Fig. 35.8 (continued)

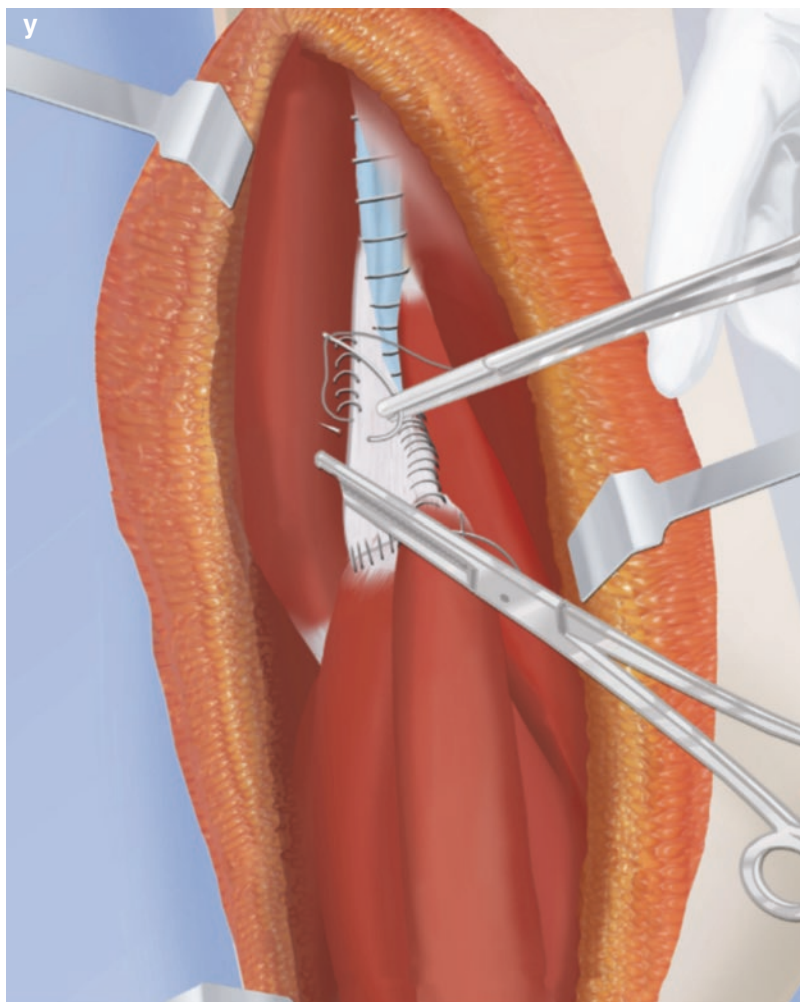


Fig. 35.8 (continued)

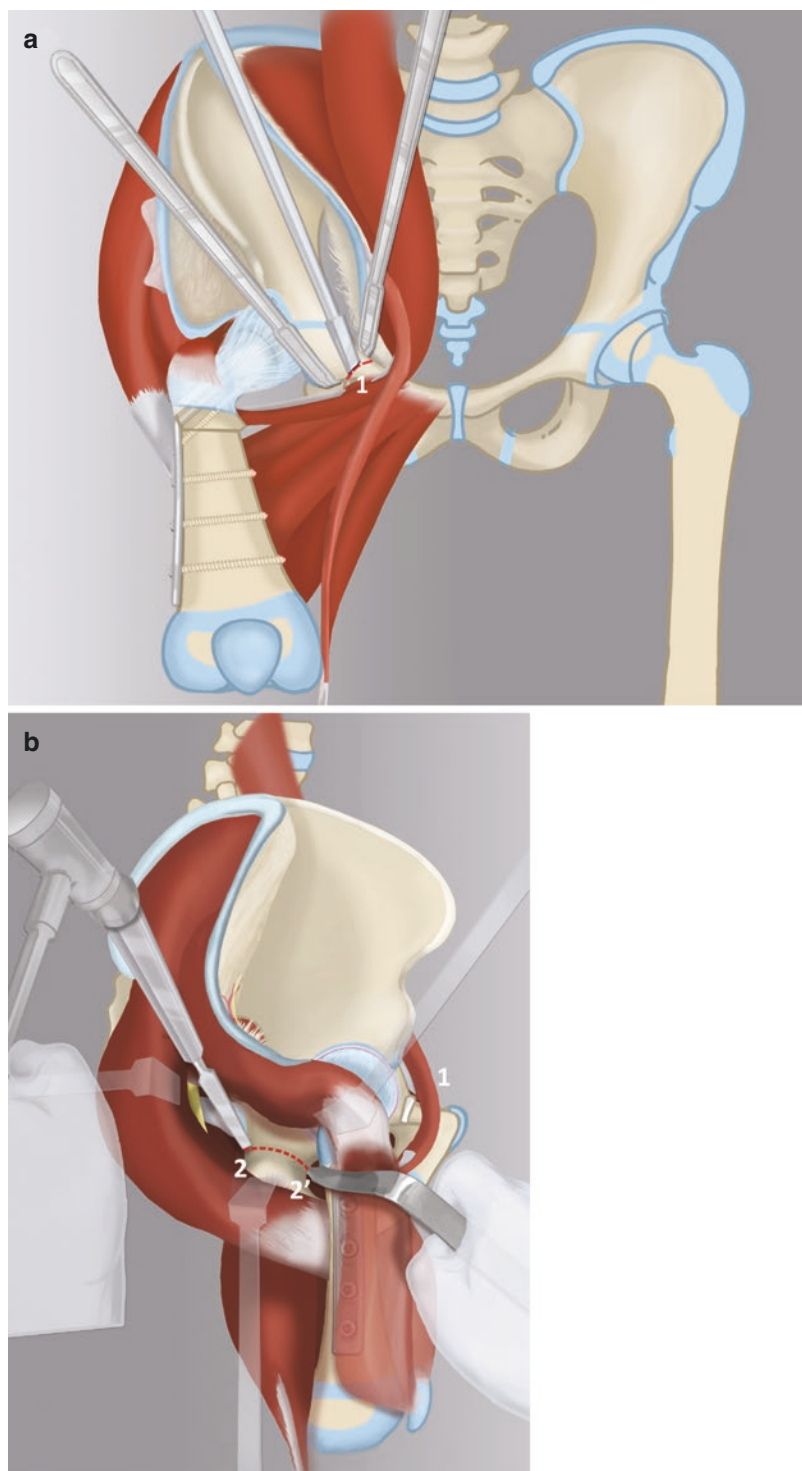


Fig. 35.9 (a–o) Periacetabular triple osteotomy: see steps of surgery corresponding to each figure. (© 2014 The Paley Foundation, with permission. All rights reserved)

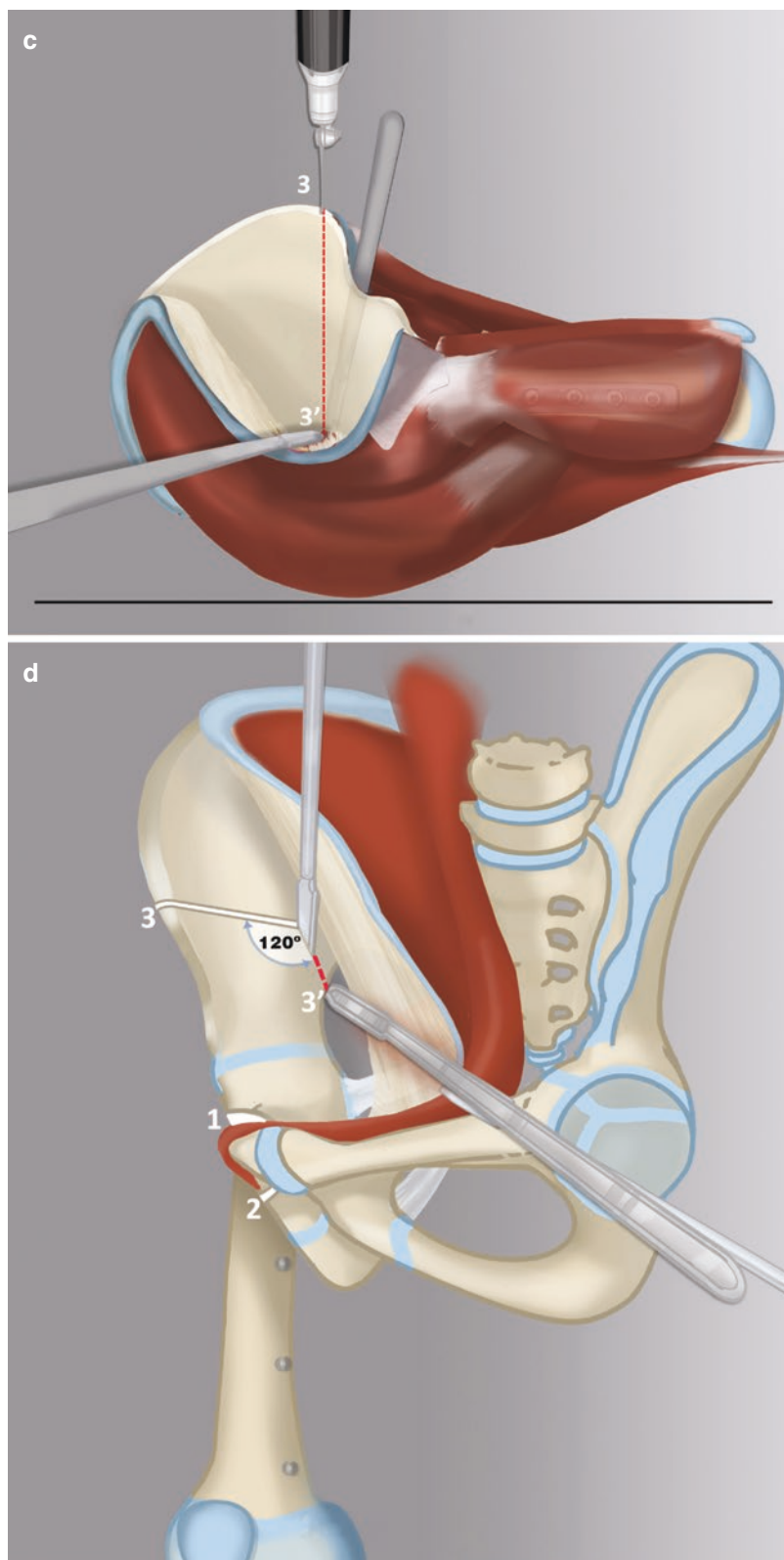
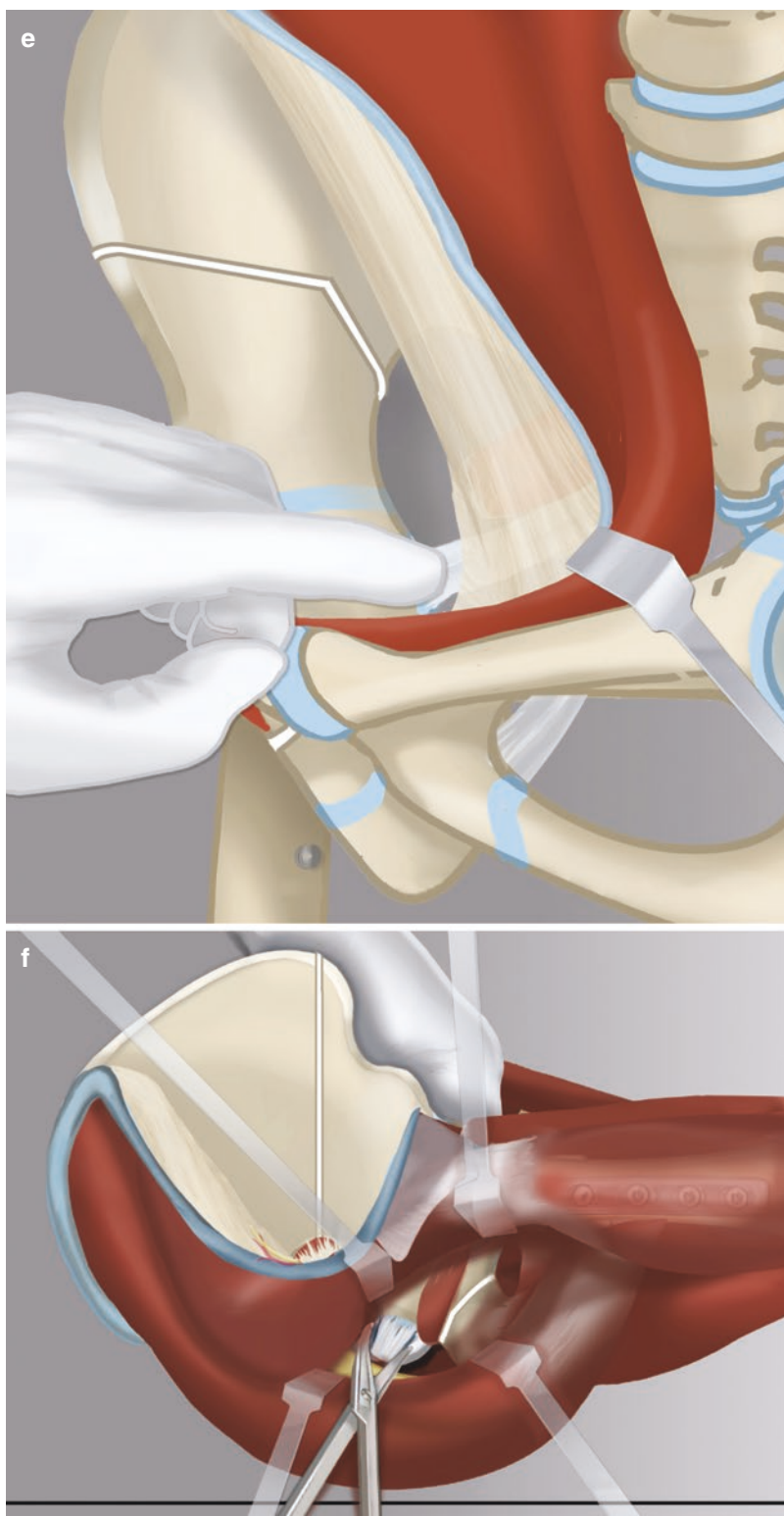
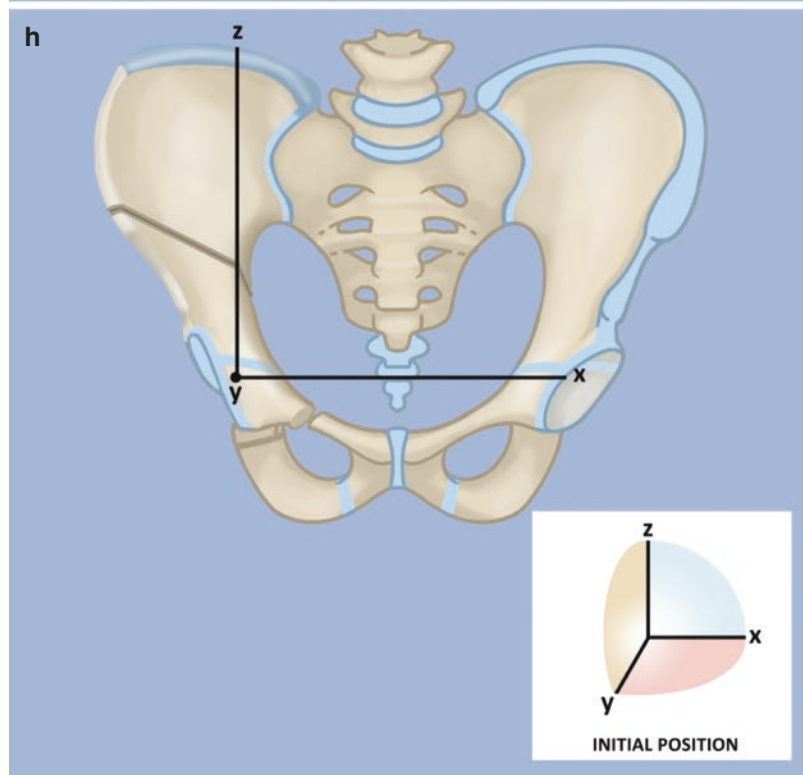
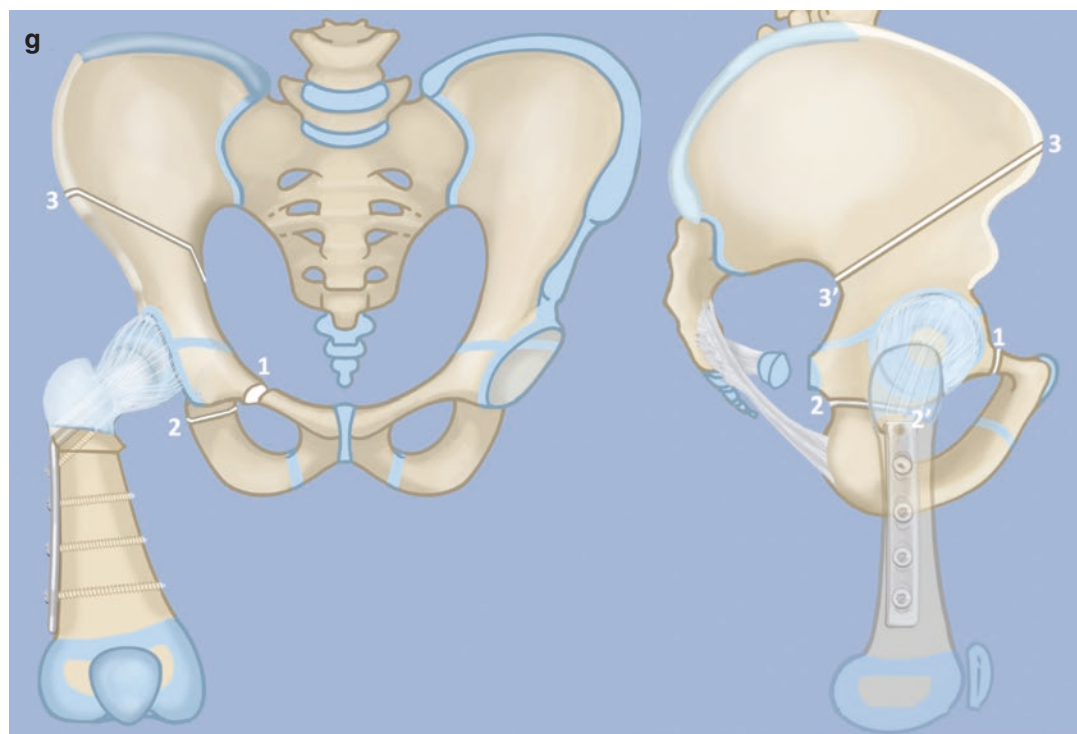


Fig. 35.9 (continued)



(continued)



(continued)

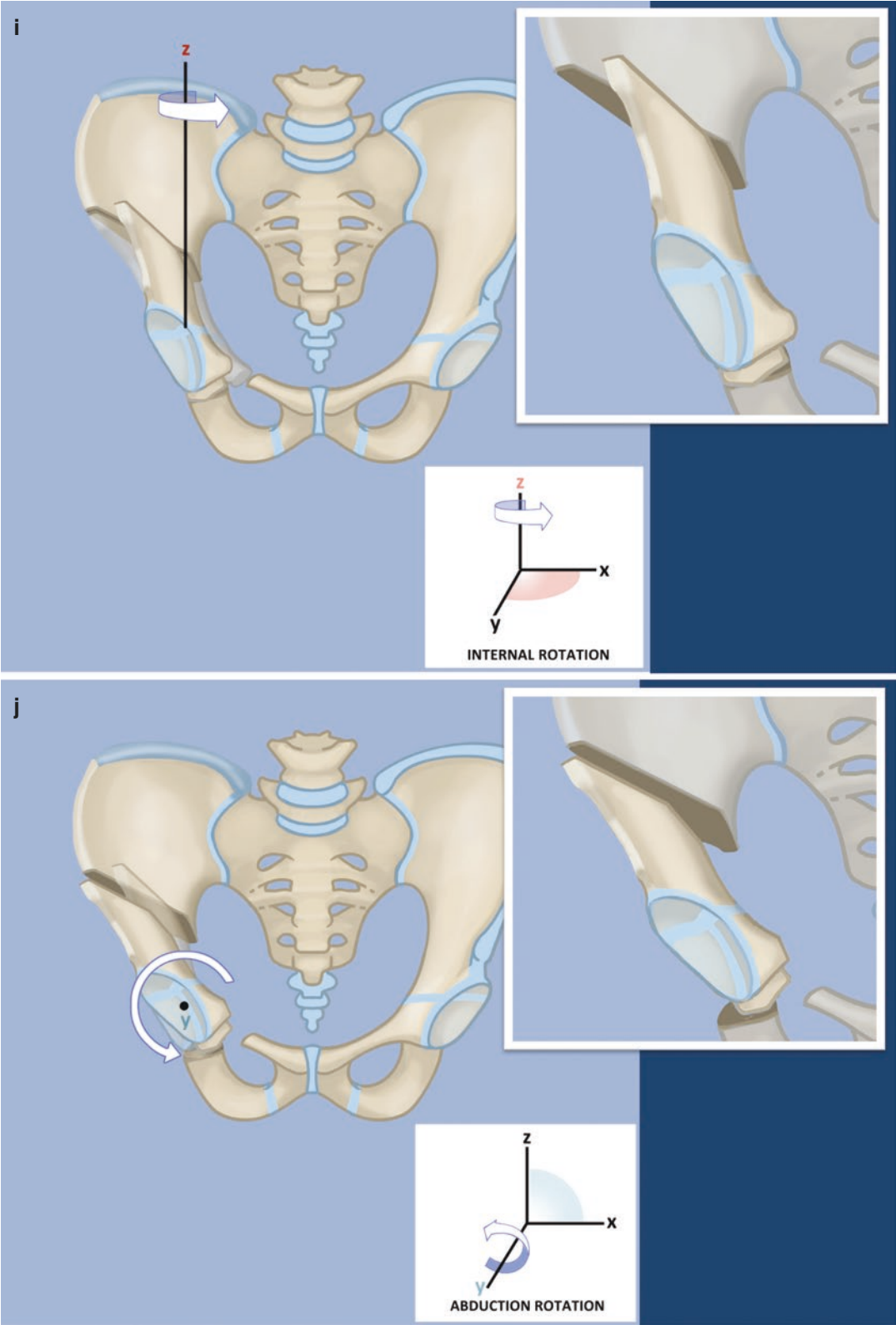


Fig. 35.9 (continued)

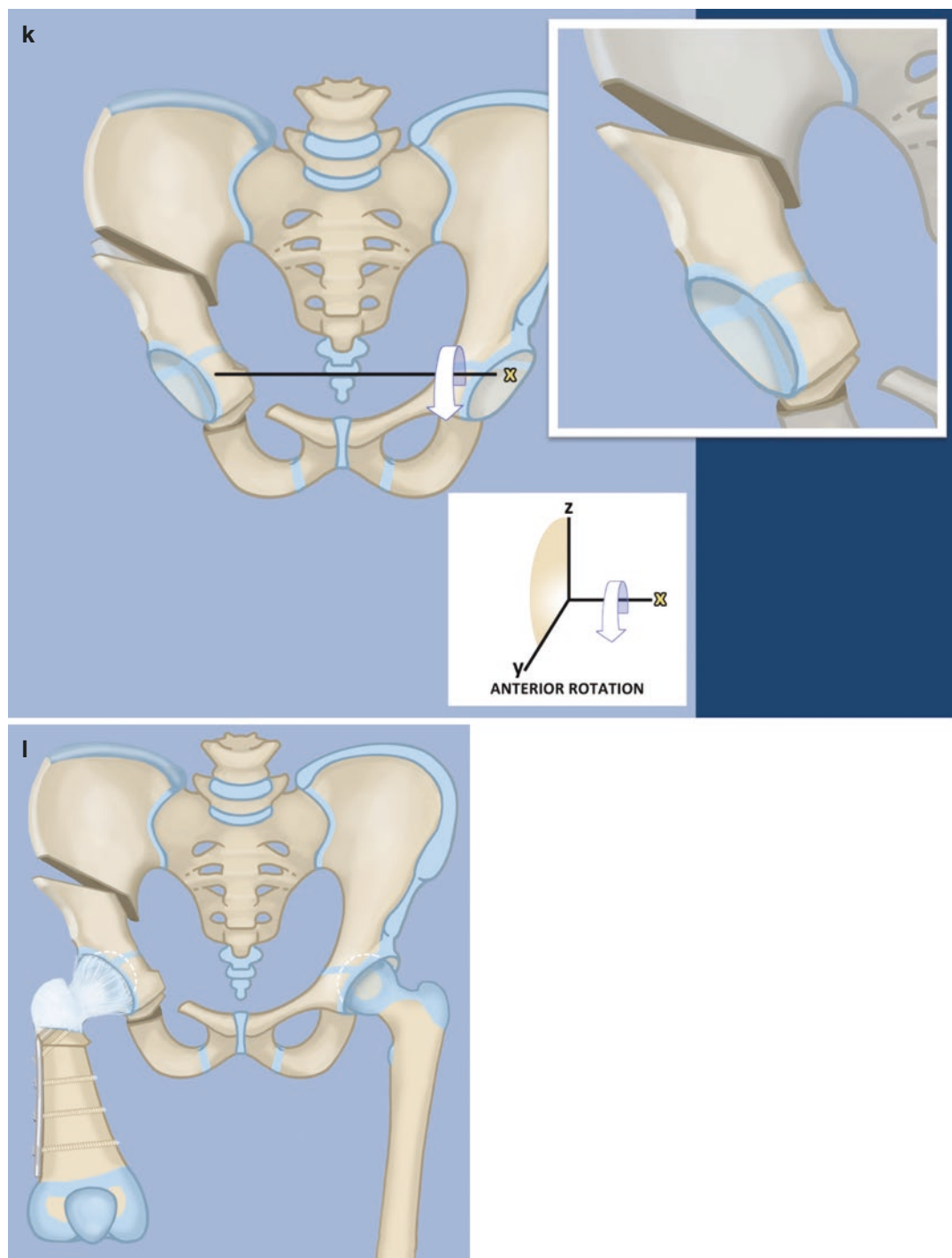


Fig. 35.9 (continued)

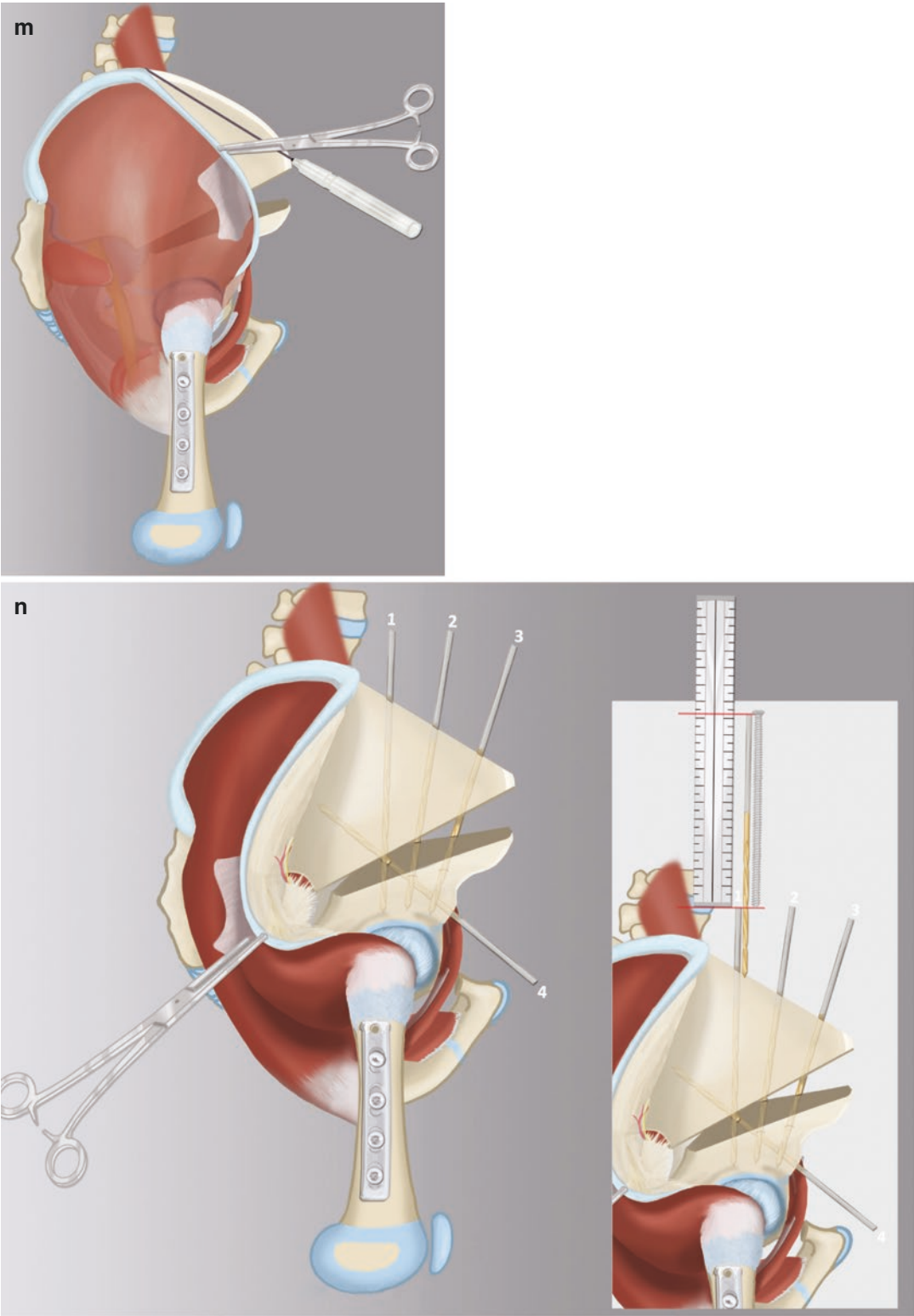


Fig. 35.9 (continued)

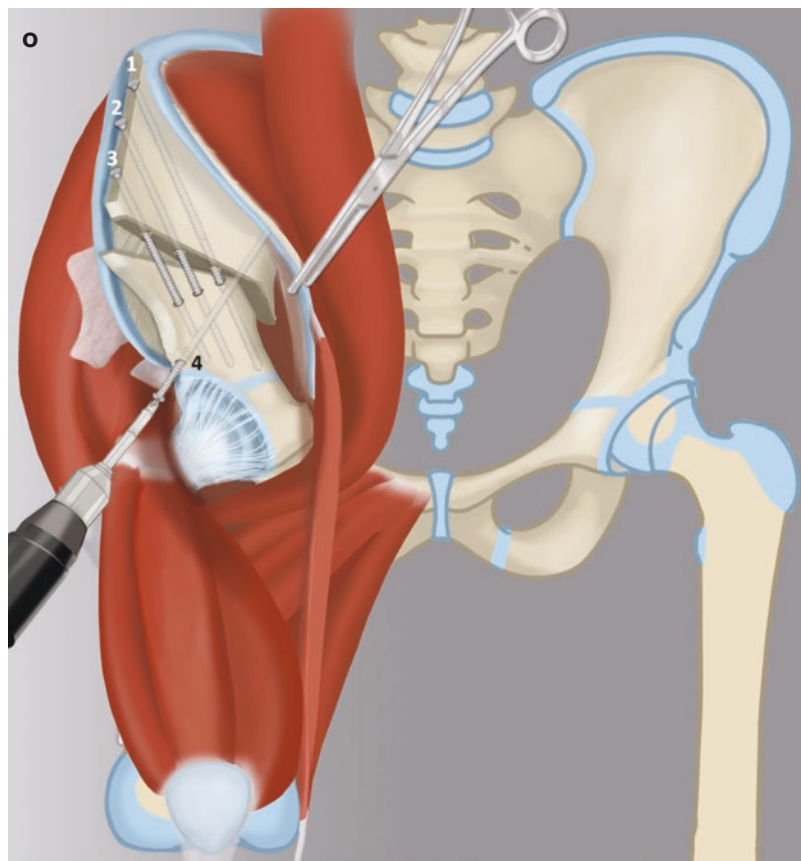


Fig. 35.9 (continued)

2. *Incision* (see Fig. 35.7b). With the leg fully extended, a long mid-lateral incision is made from the top of the iliac crest to the tibial tuberosity. The incision is kept as straight as possible, passing over the proximal femoral “bump” and continuing longitudinally towards Gerdy’s tubercle and the tibial tubercle. The incision is carried down to the depth of the underlying fascia lata and iliotibial band.
3. *Flap elevation* (see Fig. 35.7c). The subcutaneous tissues and skin are elevated as one large flap anteriorly and posteriorly off the fascia of the thigh and pelvic region. The fat is adherent to the fascia and should be dissected preferably with an electrocautery. The electrocautery should be held flat, parallel to the plane of dissection. This can be quite technically difficult until one learns how to separate the fat without perforating the fas-

cial layer or leaving fat behind. It is important not to incise or damage the fascia if it is being used for knee ligament reconstruction (SUPERknee procedure). Dissection may also be carried out with scissors. Anteriorly, the flap is extended just medial to the Smith-Peterson interval between the tensor fascia lata (TFL) and sartorius) proximally. Posteriorly, the subcutaneous flap is elevated to just posterior to the intermuscular septum. Distally, reflect the flap to the patella if no ligament reconstruction is to be done, and to the patellar tendon if ligament reconstruction is needed. The fascia lata is now fully exposed from the patella to a couple centimeters posterior to the intermuscular septum distally and from the anterior edge of the TFL to the mid gluteus maximus proximally.

4. *Fascia lata release* (see Fig. 35.7d, e). The fascia is incised at the TFL-sartorius interval making sure to stay on the TFL side in order to avoid injury to the lateral femoral cutaneous nerve. The fascial incision is extended distally to the lateral border of the patella ending at the tibia. The posterior incision of the fascia lata starts distally and posterior at the intermuscular septum and extends proximally to overlie the gluteus maximus in line with the incision. The gluteus maximus (GMax) should be separated from the overlying fascia anterior to the posterior fascial incision. The fascia should be retracted anteriorly and away from the underlying muscle, while the GMax should be dissected off of the fascia and the intermuscular septum that separates it from the TFL. The GMax should not be split in line with the fascial incision to avoid denervating the muscle anterior to the split. It can now be reflected posteriorly to allow exposure of the greater trochanter, piriformis muscle and sciatic nerve.

If knee ligamentous reconstruction is planned, the fascia lata is cut proximally and anteriorly at the musculotendinous junction. The fascial cut should be a step cut or sloped posteriorly and proximally to include a longer fascia segment posteriorly from the fascia that was dissected off of the GMax. The fascia lata is reflected distally to Gerdy's tubercle. The TFL can be left in place without further dissection. It does not have to be separated from the underlying gluteus medius (GMed). The two muscles are often adherent to each other, and it may be difficult to differentiate the muscle fibers. The distinguishing feature is that the GMed fibers insert on the greater trochanter while the TFL does not. The distal fascia lata becomes the iliotibial band and blends with the underlying lateral knee capsule, which may be partially reflected with the iliotibial band. The fascia should be mobilized all the way until Gerdy's tubercle. The fascia can then be divided into two halves using a straight pair of scissors. It should be kept moist while the rest of the surgery proceeds. The two limbs

of the fascia are ready for later use in the SUPERknee procedure.

5. *Hip flexion contracture releases* (see Fig. 35.7f, g). The dissection is carried beneath the sartorius to find the rectus femoris tendon. The rectus femoris tendon insertion is identified at the anterior inferior iliac spine. The constant ascending branch of the lateral femoral circumflex artery and vein is cauterized prior to cutting the tendon. The conjoint rectus femoris tendon (distal to the split into reflected and direct heads) is cut and allowed to retract distally. Care should be taken not to go too distal on the rectus femoris to avoid injury to its innervating branch of the femoral nerve. In the more dysplastic and deformed cases the entire femoral nerve may be lying immediately adjacent to the rectus femoris tendon especially if there is a lot of upward migration of the proximal femur. Just medial to the rectus is the iliopsoas muscle. The iliocapsularis muscle (capsular origin head of iliopsoas muscles) can also be seen here. The femoral nerve lies on the antero-medial surface of the iliopsoas muscle. Before looking for the psoas tendon, the femoral nerve should be identified and decompressed below the inguinal ligament. The posterior aspect of the iliopsoas muscle belly is now elevated from lateral to medial. The psoas tendon is located on the postero-medial surface in the substance of the muscle. The tendon is exposed and cut. Any remaining flexion contracture of the hip is due to the gluteus medius and minimus (the part of these muscles originating anterior to the center of rotation of the femoral head in the sagittal plane), and the anterior fascia of thigh. The release of the gluteus medius and minimus muscles is accomplished by the abductor muscle slide technique (see step 7). If the anterior thigh or sartorius fascia are still tight, they can also be released, taking care not to injure the lateral femoral cutaneous nerve, which should be identified and decompressed under the inguinal ligament.
6. *External rotation contracture release* (see Fig. 35.7h). The piriformis tendon is con-

tracted and prevents internal rotation of the hip. It should be released off of the greater trochanter. To gain access to see this tendon, the gluteus maximus muscle must be retracted posteriorly. It can be left attached at its distal insertion on the femur. It can be swept posteriorly as a large sheet of muscle. The greater trochanter can be identified by palpation. The gluteus medius muscle posterior border is very distinct and proceeds down to the greater trochanter where it inserts. Deep to the medius is the gluteus minimus, and just distal to the minimus is the piriformis muscle. Its tendon can be palpated through its muscle. It may be difficult to identify the piriformis from the minimus. Care should be taken to avoid dissection at the distal border of the piriformis tendon. This is where the medial femoral circumflex branch anastomoses with the inferior gluteal artery branch. To get good visualization it is helpful to have an assistant lift up the patient using a sharp Senn retractor (also known as a *cat's paw* retractor). The sharp end is inserted into the posterior edge of the bump on the femur and the femur is pulled anteriorly (almost like lifting the hip off, of the table with this retractor). The entire piriformis is transected about 1 cm from its insertion onto the trochanter. The sciatic nerve can be identified and if necessary decompressed. It is more posterior and medial to the trochanter and runs deep to the piriformis.

7. *Abductor muscle slide* (see Fig. 35.7i). The abductors may not appear to be tight on first inspection because of the coxa vara. Adduction into a true AP of the hip, with the neck oriented normally in the acetabulum, is now restricted by the gluteus medius and minimus since the fascia lata has already been cut. Furthermore, the Dega osteotomy, which lengthens the height of the ilium, makes the abductors even tighter. The abductors should be detached at their origin and not their insertion. This avoids changing the muscle-tendon length ratio and avoids weakening the hip abductors, avoiding a lurch or Trendelenburg gait.
8. *Elevation of quadriceps* (see Fig. 35.7j). The quadriceps are now elevated off of the femur in a subperiosteal fashion. Since the femur is so short, the exposure may extend as far as the distal femoral physis. The perforator vessels need to be cauterized as the quadriceps is detached from the linea aspera. Proximally, the vastus lateralis should be elevated off of part of the cartilage of the greater trochanteric apophysis by sharp dissection. Stay anterior to the gluteus maximus tendon which does not need to be dissected from the femur.

The subcutaneous tissue flaps should be elevated to provide adequate exposure to the iliac crest apophysis. There is a tendency to have inadequate posterior exposure, and the flaps should be elevated just beyond the highest lateral point of the apophysis. The anterior extent is the anterior superior and inferior iliac spines, which has been exposed for the release of the rectus femoris tendon. The abdominal external oblique muscles are partially released off of the entire length of the apophysis. Split the cartilaginous apophysis from the anterior inferior iliac spine to the anterior superior iliac spine, and then continue posteriorly splitting from anterior to posterior along the iliac crest. This should be done with a #15 blade. To know where to split, pinch the apophysis between thumb and index finger of the hand not holding the knife. Stay in the middle of the apophysis along its entire length, pushing down hard with the knife blade until one feels bone. Using a periosteal elevator, pop off the apophysis from the ilium. This should be done at multiple sites to get the entire apophysis to peel back as a unit from the ilium. The apophysis and lateral periosteum are reflected distally, thus relaxing the abductor muscles. The medial half of the apophysis is reflected medially with the iliacus muscle. Since some of the abductors act as flexors of the hip, the abductor slide helps eliminate any remaining flexion deformity of the hip. Furthermore, the iliacus muscle slide also relaxes any residual tension in the iliopsoas.

9. *Arthrogram (see Fig. 35.8a).* A hip arthrogram is now performed using a 20 gauge spinal needle. With the trocar inside, the needle is placed into the hip joint from the anterolateral side. Traction of the femur may facilitate placement. Once the needle appears to be in the joint on the image intensifier, the trocar is removed and normal saline is injected. If the needle is in the joint the saline should go in with little pressure, and when the syringe is removed from the needle, the saline should drip back out. These signs confirm that the needle is in the joint space. The arthrographic dye can now be injected into the hip joint to outline the femoral head, acetabulum, and femoral neck. The reason for this two step arthrogram is that if a false injection of dye occurs, it will obscure the visualization of the hip joint. The two step method is a more secure way of confirming intra-articular needle placement.
10. *Guide wire insertion (see Fig. 35.8b–d).* Since the abduction, flexion, and external rotation contractures have all been released, the femoral head and neck can now be placed in a neutral orientation to the pelvis by extending and maximally adducting the lower limb across the opposite leg. A guide wire should now be drilled up the center of the femoral neck to guide the insertion of a fixed angle fixation device. Since the femoral neck is unossified and short, it is very difficult to drill a guide wire at the correct angle up the femoral neck. The goal is to create a 130° neck-shaft angle and a medial proximal femoral angle (MPFA) of 85° (see Fig. 35.8d). In the normal femur, the angle between the neck-shaft line and the tip of the greater trochanter to center of femoral head line is 45°.

The first guide wire is inserted from the tip of the greater trochanter to the center of femoral head (see Fig. 35.8b). Since the tip of the trochanter is cartilaginous in young children, it cannot be seen radiographically. The tip of the trochanter is located by palpation using the wire tip. From this point, the wire is then drilled towards the center of the femoral head as shown in the arthrogram.

The image intensifier is placed into the lateral view and the leg rotated until a bull's-eye of three concentric circles is seen. This is formed by the overlapping dye shadows: the outermost circle is the femoral head, the middle circle is the femoral neck, and the inner circle is the ossific nucleus of the femoral head. A second wire should be drilled into the center of the bull's-eye at a 45° angle to the first wire (see Fig. 35.8c). Using a depth gauge or another wire of the same length as the second wire, measure the amount of wire inside the femoral neck by placing it alongside the second wire and measuring the difference in length between the two wires. This will be the length of the blade of the blade plate to be used. The position of the neck wire can also be confirmed by flexing the hip to 90° and looking at a frog-leg lateral of the neck.
11. *Blade plate insertion (see Fig. 35.8e–h).* The cannulated chisel for the blade plate should now be hammered up the femoral neck guided by the second guide wire (see Fig. 35.8e). The chisel should be rotated until it is perpendicular to the posterior aspect of the greater trochanter (see Fig. 35.8f). This will guide it to the correct angle in the sagittal plane. Tap the chisel out of the femur and reinsert the guide wire in its previous position. Insert the appropriate length 130° blade plate over this wire to the depth of the bend of the plate (see Fig. 35.8g). Make sure on the image intensifier that the tip of the blade is not too deep into the femoral head. Check its position on AP and lateral planes, as well as using the approach-withdrawal technique with live fluoroscopy to ensure that the blade is not advanced too close to the articular surface of the femoral head. If the blade is suspected of being too long, then replace it with one with a shorter length. Furthermore, if plate placement is off-center, there is greater risk of protrusion into the joint. The posterior edge of the plate should be parallel to the back of the greater trochanter. The femur diaphysis is usually flexed to the plate (see Fig. 35.8h).

12. *Subtrochanteric osteotomy (see Fig. 35.8i, j).*
The femur should be cut perpendicular to the shaft of the plate, starting just below the bend in the plate (see Fig. 35.8i). This cut should be below the level of the greater trochanter cartilage. To guide this cut, drill a wire perpendicular to the plate. Keep the plane of the saw blade perpendicular to the plate in all planes. The width of the perpendicular cut surface should be as wide as the femoral diaphysis. A second subtrochanteric osteotomy should be made oriented less than 90° to the first osteotomy towards the base of the femoral neck to remove the bone protruding medially (Fig. 35.8j). The femoral head and neck can be manually tested for any residual impingement, removing any blocks to achieving 90° of hip flexion. The antero-medial corner often needs to be excised to prevent impingement.
13. *Periosteum release (see Fig. 35.8k–m).* After the second osteotomy, the distal femur is easily exposed and the surrounding periosteum is peeled off circumferentially. Medially, it is very thick and restricts correction of the varus and rotation deformity. Cut the periosteum transversely around the femur, carefully separating it from the surrounding muscle (see Fig. 35.8k). Be careful to avoid injury to the profunda femoris and its perforators, which pass immediately under the periosteum. Cutting the periosteum allows the thigh to stretch longitudinally, reducing the amount of shortening required of the femur. The hip adductors become the main tether to the length of the femur (see Fig. 35.8l). The anteromedial corner of the femur should be resected to prevent impingement in flexion (see Fig. 35.8m).
14. *Pelvic Osteotomy: Option 1—Paley Modified Dega Osteotomy (Paley-Dega) (see Fig. 35.8n, o).* It is preferable to perform the pelvic osteotomy at this juncture since it can affect the amount of femoral shortening and rotation. The iliac periosteum is reflected back to the edge of the acetabulum and to the sciatic notch. The periosteum should also be

dissected off the anterior wall of the sciatic notch, feeling for the soft cartilage of the triradiate cartilage as it separates the ilium from the ischium. Using the image intensifier, a guide wire is drilled approximately 2 cm proximal to the lateral edge of the acetabulum towards the triradiate cartilage medially. Start the osteotomy posteriorly parallel to the sciatic notch anterior border. Start near the triradiate cartilage and continue proximally. Stay only a few millimeters anterior to the sciatic notch at the distal end of this limb of the cut. Curve anteriorly towards the guide wire and incline the cut medially towards the triradiate parallel to the guide wire (see Fig. 35.8n). The osteotomy remains unicortical except at the most anterior end where it exits anteriorly as the osteotomy heads towards the pubic eminence. The osteotomy never exits through the medial wall. This is the Paley Modification. The original Polish Dega osteotomy exits through the medial wall and heads towards the top of the sciatic notch. The Paley-Dega truly hinges on the triradiate cartilage medially and posteriorly. The osteotomy is levered distally to bring the roof of the acetabulum down. A laminar spreader is used to distract the osteotomy (see Fig. 35.8o). The posterior vertical limb of the osteotomy extending down to the triradiate cartilage at the ischium allows for greater bending and greater lateral coverage. It is a myth that the Dega osteotomy gives posterior coverage since the posterior lip is part of the ischium and this osteotomy is only iliac. The original Dega, as well as subsequent publications of this osteotomy, goes through the inner table of the pelvis, especially anteriorly and heads for the upper end of the sciatic notch. The Paley-Dega is unicortical and extends farther posterior and distal to also hinge near the triradiate at the level of the ischium. In this manner, there is true hinging in a three dimensional way near the triradiate. Even the anterior part of the cut does not exit the cortex and extends to the triradiate junction between the ilium and pubis. The bump

under the buttocks should be removed at this stage. This allows one to assess the coverage of the femoral head in the frontal plane. The laminar spreader can be distracted as needed to gain additional coverage and reorientation of the acetabular source. The laminar spreader should be kept posterior to avoid increasing the anterior coverage and creating impingement. The dysplasia of the acetabulum in CFD cases is postero-lateral [2, 3]. The Dega osteotomy only provides lateral coverage. At this point, the femoral shortening should be carried out and the excised bone segment cut to fit the opening wedge gap of the pelvic osteotomy. Additional bone from the iliac crest, which is resected during the abductor slide, may be inserted to fill the remaining space.

Pelvic Osteotomy: Option 2—Paley Modification of Periacetabular Triple Osteotomy (Paley PATO) (Fig. 35.9). Pubis: The pubis is exposed subperiosteally by reflecting the medial iliac apophysis and periosteum more medially. The triradiate cartilage arm at the pubis is exposed and the dissection carried out just distal to it. The superior pubic ramus can be cut under direct vision under the protection of two Hohmann retractors with an osteotome (see Fig. 35.9a). Ischium: The ischium is exposed by returning to the back of the femur and finding the sciatic nerve again. The nerve is followed to the ischium. To avoid stretching the nerve, do not place a retractor between the nerve and the ischium. A Hohmann retractor can be placed anterior to the ischium. Subperiosteal elevation of the ischial periosteum is carried out. The ischium should be cut under direct vision near the junction where it forms the inferior wall of the acetabulum, distal to the triradiate cartilage (see Fig. 35.9b). Ilium: The ilium is cut with a saw from the anterior superior iliac spine towards the apex of the sciatic notch laterally (Fig. 35.9c). Medially it aims for the junction of the true and false pelvis in line with the sciatic notch (see Fig. 35.9d). As the cut reaches the junction of the true pelvis, an osteotome is used to change the angle of the

cut (see Fig. 35.9d). The osteotome is about 120° to the saw cut. This bend in the cut rounds off the corner of the distal segment and creates a spike of bone on the proximal segment. This increases the surface area and creates a posterior buttress while making the distal segment rotate more easily with less distraction. This third bone cut completes the triple osteotomy (see Fig. 35.9e). Sacrospinous ligament release: For large corrections, it is important to release the tether of the sacrospinous ligament. In particular this ligament limits the amount of internal rotation used to achieve posterior coverage and the abduction used to achieve supero-lateral coverage. This ligament can be palpated after dissecting the medial iliac periosteum off of the quadrilateral plate inside the true pelvis. A finger can be placed on the tip of the ischial spine, and the ligament is then felt (Fig. 35.9e). Using proprioception, a finger from the other hand can be used to palpate the finger that is on the ligament. Make sure the sciatic nerve, which can be visualized laterally, is not in the way. With the ligament isolated in this manner, it can be cut with a blunt pair of curved Mayo scissors from the lateral side, cutting directly onto one's own finger (Fig. 35.9f). To make this easier to visualize, the acetabular bone segment can be rotated internally to deliver the spine more laterally (Fig. 35.9g). Since CFD is associated with a hypoplastic acetabulum, there is usually posterior as well as lateral deficiency. To gain posterior and lateral coverage, the acetabular segment should first be rotated internally along the long axis of the body (z-axis) (Fig. 35.9h-i). This moves the posterior lip laterally increasing the posterior coverage. The second manipulation is to rotate the acetabular segment laterally (abduction) to increase lateral coverage (y-axis) (Fig. 35.9j). These two movements decrease the anterior coverage. It is therefore essential to rotate the acetabular fragment anteriorly (flexion) to restore anterior coverage (x-axis) (Fig. 35.9k-l). To rotate internally, a lion-jaw bone clamp is placed antero-posteriorly, superior to the

acetabulum and the bone fragment rotated internally. It can also be placed around the pubis to lever the acetabulum laterally. If the acetabular fragment does not move sufficiently, then each osteotomy sites should be checked for completeness. The ischial osteotomy is often the culprit, and the periosteum around the ischium may need to be divided. Fixation of the triple osteotomy is achieved using long 3.5 mm screws from the ilium to the acetabular fragment. However, because of the abductor slide, the proximal part of the iliac wing must be resected prior to screw fixation. The level of resection is determined by pulling up the apophysis with the femur held in a neutral position (see Fig. 35.9m). The bone proximal to the level the apophysis should be resected (see Fig. 35.9n). Four equal length drill bits are used to fix the osteotomy, three antegrade and one retrograde. A same sized drill bit is used to compare lengths with the drill bits inside the bone to determine the screw lengths (see Fig. 35.9n). One by one, the drill bits are removed, and replaced with solid, non-cannulated screws, making sure that they do not enter the triradiate cartilage or the hip joint (see Fig. 35.9o).

15. *Femoral shortening (see Fig. 35.8p–r).* The distal femur is now mobile and can be corrected into valgus and rotated internally. The distal femur is too long to fit end-to-end with the proximal femoral cut. The two ends should be overlapped, and a mark should be made at the point of overlap (see Fig. 35.8p). The distal femur should be shortened at this level. A wire is drilled perpendicular to the femur at the level of the osteotomy and a saw is used to cut, using frequent irrigation to prevent heat necrosis (see Fig. 35.8q). The segment of bone is kept moist on the back table for use as bone graft for the Dega osteotomy. This is usually a trapezoid shaped piece about 2–5 cm long (see Fig. 35.8r).
16. *Bone grafting Dega osteotomy (see Fig. 35.8r; s).* The segment of bone from the femoral shortening is cut to the dimensions needed to support the opening wedge Dega osteotomy (see Fig. 35.8r). The dimension of

the graft needed is measured from the size of the opening wedge base using a caliper. A trapezoidal shaped graft is then fashioned from the femoral shortening segment. It is inserted into the pelvic osteotomy to support and stabilize it (see Fig. 35.8s).

17. *Distal femur fixation and internal rotation (Fig. 35.8s–v).* The femur is now brought to the plate (see Fig. 35.8s). The bone ends should oppose without tension. The femur is internally rotated to correct the external torsion deformity. To adjust the femur to the correct anteversion, the guide wire should be reinserted into the cannulation of the plate to show the orientation of the femoral neck. The knee should be flexed to 90° and the angle between the wire and the frontal plane of the femur as judged by the perpendicular plane to knee flexion is observed (see Fig. 35.8t). This wire should appear at least 10° anteverted, relative to the knee. The most distal hole in the plate can now be drilled with the femur held in this rotation (see Fig. 35.8u). The drill hole should be made at the distal edge of the hole to compress the osteotomy with screw insertion. Two more screw holes are drilled and screws are inserted. The most proximal hole in the plate is designed to drill parallel to the blade of the plate and secures the plate to the proximal femur. The wire in the cannulated hole can be used to guide the drill bit. In type 1b cases, the blade of the plate and the oblique screw goes across the proximal physis and into the femoral head (see Fig. 35.8v). In type 1a cases with a horizontally oriented growth plate, neither the blade nor the screw should cross the growth plate of the upper femur. In type 1a cases with a vertically oriented growth plate, the blade but not the screw should cross the physis.
18. *Bone Morphogenetic Protein2 (BMP2) insertion (see Fig. 35.8v).* In type 1b neck cases, BMP should be inserted into the upper femur to induce ossification of the cartilaginous neck of the femur. A wire is drilled proximal and parallel to the guide wire in the cannulation of the plate. A 4.0 mm hole is then

drilled over this guide wire. The drill hole should extend all the way to the ossific nucleus. BMP-2 (Infuse, Wright Medical, Memphis TN, USA) is then prepared on collagen sponges. Radiocontrast dye can also be applied to the collagen sponges. The sponges are loaded into a metal tube whose outer diameter is 4 mm (Craig needle biopsy set). This cannula is then inserted into the drill hole. Using a blunt trochar the sponge is pushed out of the tube inside the femoral neck. Using the image intensifier it is possible to see the sponge in the unossified neck due to the radiocontrast dye on the sponge. It should be emphasized that such use of BMP2 (Infuse implant) is an off label use of this product since the product is not FDA cleared in children. Usually two sponges are used in one drill hole. Bone wax is used to seal the lateral entry hole to prevent leakage of BMP2 and heterotopic ossification.

19. *Iliac wing osteotomy (see Fig. 35.8w, x).* After the pelvic osteotomy, the apophysis should be sutured back together. Due to the abductor muscle contracture, the lateral apophysis cannot reach the top of the iliac crest. Part of the crest has to be resected to allow repair of the apophysis. Putting traction on the lateral apophysis with the femur held in a neutral position, one can mark the level to which the apophysis can reach. A saw is used to cut and remove the proximal part of the iliac wing, effectively a shortening osteotomy of the ilium. The removed bone is used as graft for the Dega osteotomy (see Fig. 35.8x). It can also be used as a bone graft around the subtrochanteric femoral osteotomy. The apophysis is then repaired with a running #1 Vicryl suture. The medial and lateral halves of the apophysis should be well opposed to avoid a bifid iliac wing. The external abdominal muscles should be advanced and repaired over the apophysis as a separate layer to avoid an abdominal wall hernia (see Fig. 35.8y).
20. *Muscle repairs and transfers (see Fig. 35.8y).* The rectus femoris muscle is sutured to the

TFL. This restores its pelvic origin while lengthening this muscle at the same time. The interval between the TFL and the sartorius is closed, carefully avoiding suturing the lateral femoral cutaneous nerve. The quadriceps is sutured to the region of the linea aspera. Finally, the gluteus maximus is advanced back to the posterior border of the TFL.

21. *Closure.* If no knee releases or reconstruction are required, the fascia lata should be resected from Gerdy's tubercle. The incision can now be closed. Since there is no fascia lata, the deepest layer is the subcutaneous fat layer, called the "underlayer". One medium-sized drains are placed, exiting anterosuperiorly. The drain is secured with a clear adhesive sterile dressing (e.g. Tegaderm, 3M Medical, St. Paul MN, USA). It is important to close the wound in a fashion that the opposite layers get sutured at the same level. The deep edges of the subcutaneous underlayer are brought together with a running #1 braided absorbable suture. The Scarpa's fascia is closed with a running 2-0 braided absorbable suture. The deep dermal layer is closed with a running 3-0 braided absorbable suture, and the skin is closed using a subcuticular 4-0 monofilament suture. Dermabond™ may be used, and sterile dressings are applied.

Final radiographs are taken: an AP pelvis and lateral knee, both including the femur. The patient is then placed into a one legged spica cast. The operative limb should be placed in full hip and knee extension with the foot and ankle left free. The cast should be bivalved to allow for swelling, before leaving the operating room.

22. *Postoperative Course:* Parents are educated on cast care, hygiene and how to transport the child in the cast. The bivalved spica cast can be converted into a removable cast after about 1 week. The patient can then start gentle passive flexion and extension of the hip from 0° to 90°, as well as passive abduction. The patient remains non-weight bearing for 6 weeks. After that the spica cast is discon-

tinued. The patient is progressed to full weight bearing. Dbony healing, then the patient is progressed to full weight bearing, gait training, strengthening, and active and passive range of motion. The end goal is to restore the child to normal function before they proceed with limb lengthening.

SUPERhip Procedure for Paley Type 1b Subtrochanteric Type

The following steps are modified when treating a subtrochanteric type 1b. The deformity is often of greater magnitude and the bump more prominent. When elevating the quadriceps open the interval between the quads and the gluteus medius. This allows the quadriceps to be lifted off of the sharp bump of the subtrochanteric region. The next difference is taking down the subtrochanteric delayed ossification site (which is like a stiff pseudarthrosis site. Instead of inserting the guide wires first, break up the stiff pseudarthrosis line and separate the bone ends. Allow the distal fragment to be freed from the periosteum. This unteethers the proximal femoral segment, which now becomes more mobile. Since the femoral shaft has been removed from the proximal segment the best way to manipulate it is to apply a clamp (e.g., lion jaw) to its distal end. The guide wires can now be inserted to find the center of the femoral neck and the cannulated chisel followed by the blade plate inserted. The proximal femur needs an osteotomy perpendicular to the plate to establish a proximal bone healing surface. The rest of the procedure is as for the neck type except that no BMP or neck drill hole are needed in these cases.

SUPERhip2 Procedure (Figs. 35.10, 35.11, and 35.12): For Paley Type 2a or 2b CFD (see Fig. 35.10a) [2, 4, 5, 9, 10]

1. *Incision and initial dissection.* Use the same anesthesia, preparation, positioning and incision as for the SUPERhip procedure described previously. Create the same subcu-

taneous flap and exposure and resection of the fascia lata and iliotibial band. Release the rectus femoris tendon and decompress the femoral nerve as previously described.

2. *Psoas tendon.* Identify and dissect but do not release the psoas tendon (see Fig. 35.10b).
3. *Anterior exposure.* Separate the vastus muscles from the hip abductors anteriorly to help expose the anterior hip capsule (see Fig. 35.10b).
4. *Gluteus maximus.* Release the gluteus maximus tendon off of the femur and reflect this muscle posteriorly (see Fig. 35.10c).
5. *Sciatic nerve decompression.* Identify and free the sciatic nerve (see Fig. 35.10d).
6. *External rotators.* Release all of the external rotators off of the back of the femur. Also release the piriformis tendon off of the trochanter (see Fig. 35.10d, e).
7. *Psoas tenotomy.* Follow the psoas tendon to its insertion on the back of the femur. Release this tendon off of the femur. Try and preserve the medial femoral circumflex vessel and its ascending branch. Tag the psoas tendon for later transfer (see Fig. 35.10e, f).
8. *Hip abductors.* Release the gluteus medius and minimus tendon attachments from the greater trochanter and reflect them proximally (see Fig. 35.10g).
9. *Femoral neck fibrous anlage.* Identify the femoral neck anlage, which travels from the femoral head to the greater trochanter (see Fig. 35.10h, i). Resect this thick structure (see Fig. 35.10j).
10. *Hip capsule superior.* Make a very small incision into the hip capsule superiorly (see Fig. 35.11a).
11. *Femoral head mobility.* Confirm that the femoral head is either mobile or fused (see Fig. 35.11a).
12. *Hip capsule inferior.* Make a larger inferior capsular incision in the hip capsule (see Fig. 35.11b).
13. *Transverse acetabular ligament.* Cut this ligament (see Fig. 35.11b).
14. *Ossific nucleus.* If the femoral head is mobile, cut down to the ossific nucleus (see Fig. 35.11b).

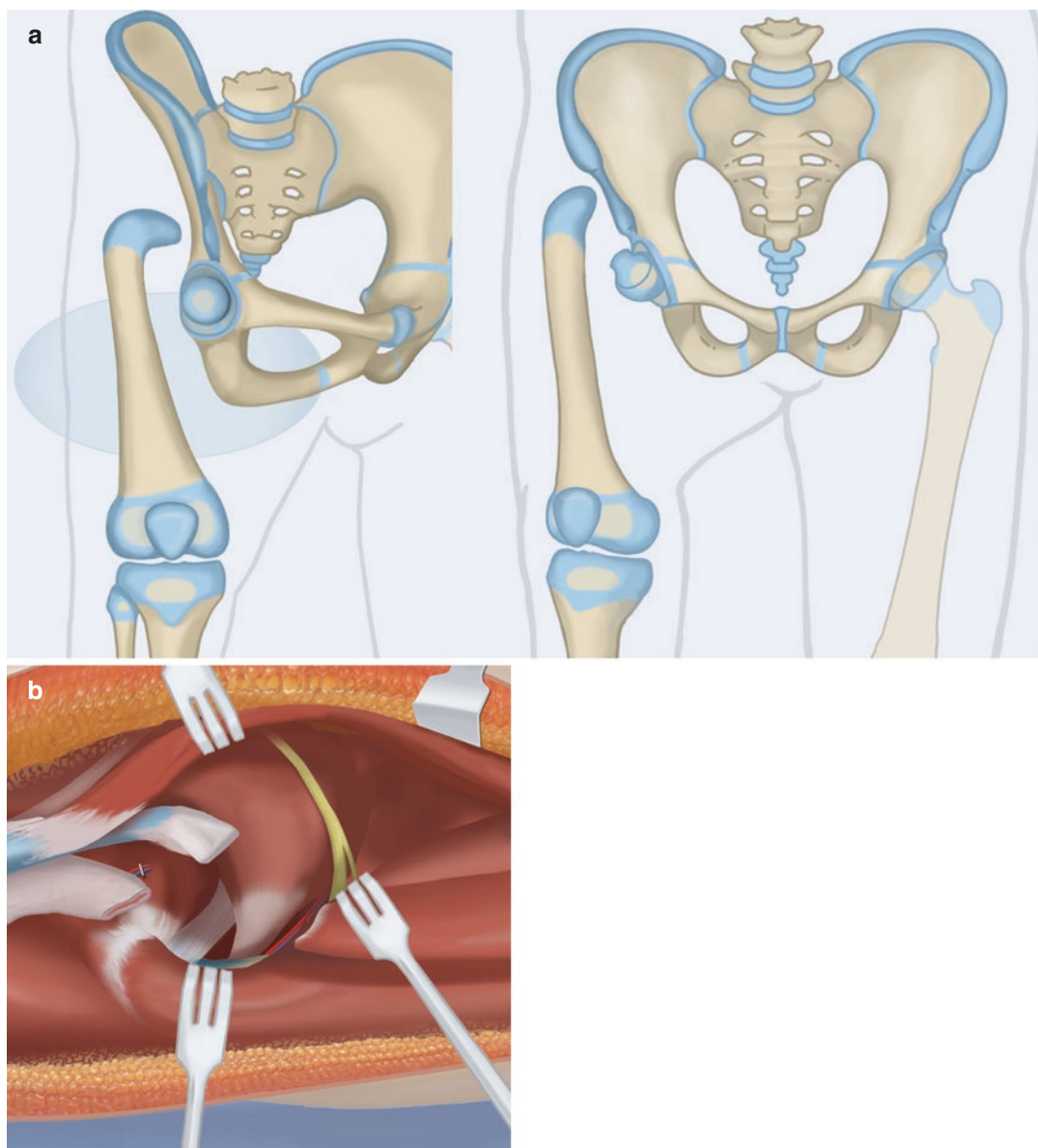


Fig. 35.10 (a–j) SUPERhip2 procedure soft tissue releases: see steps of surgery corresponding to each figure. (© 2014 The Paley Foundation, with permission. All rights reserved)

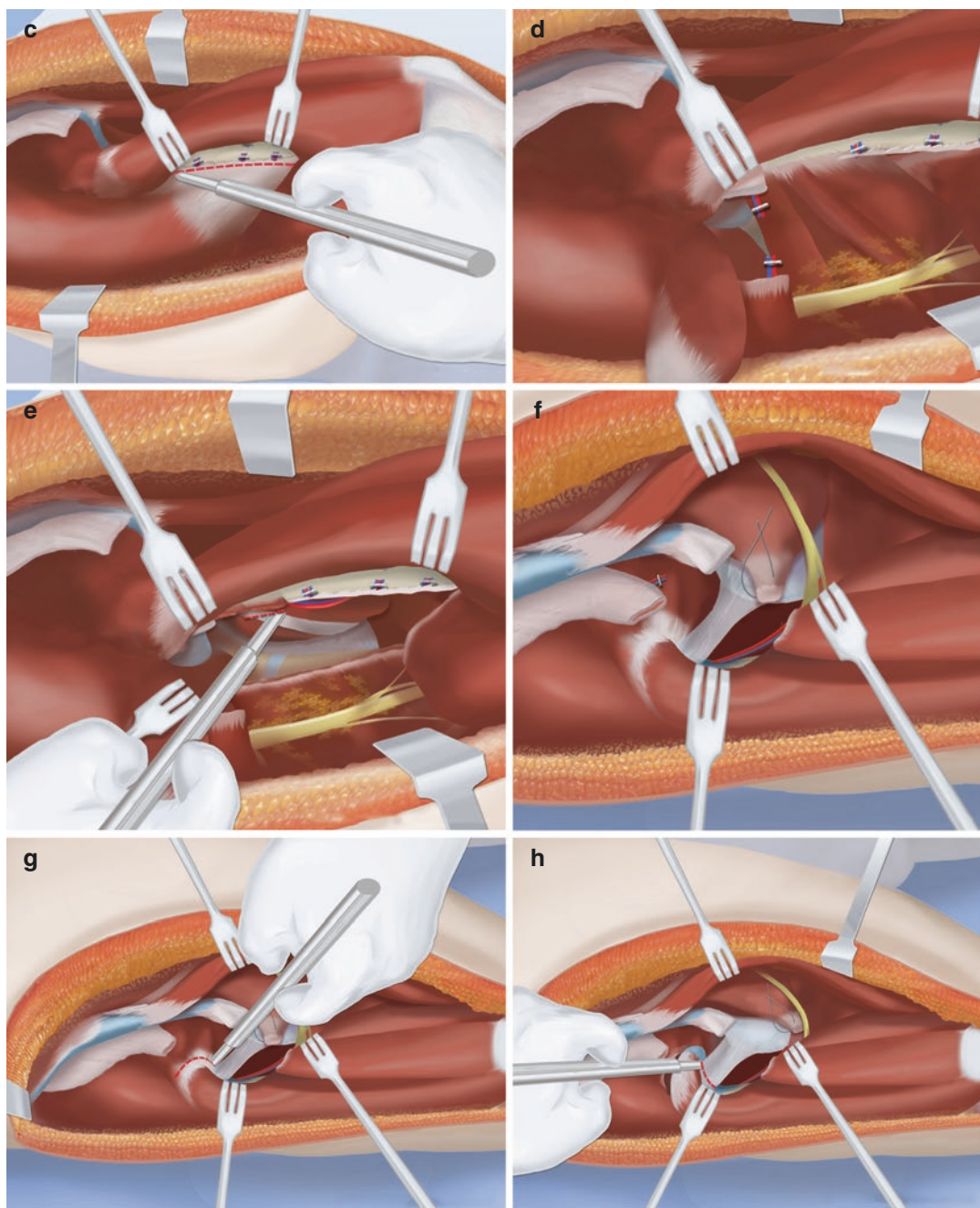


Fig. 35.10 (continued)

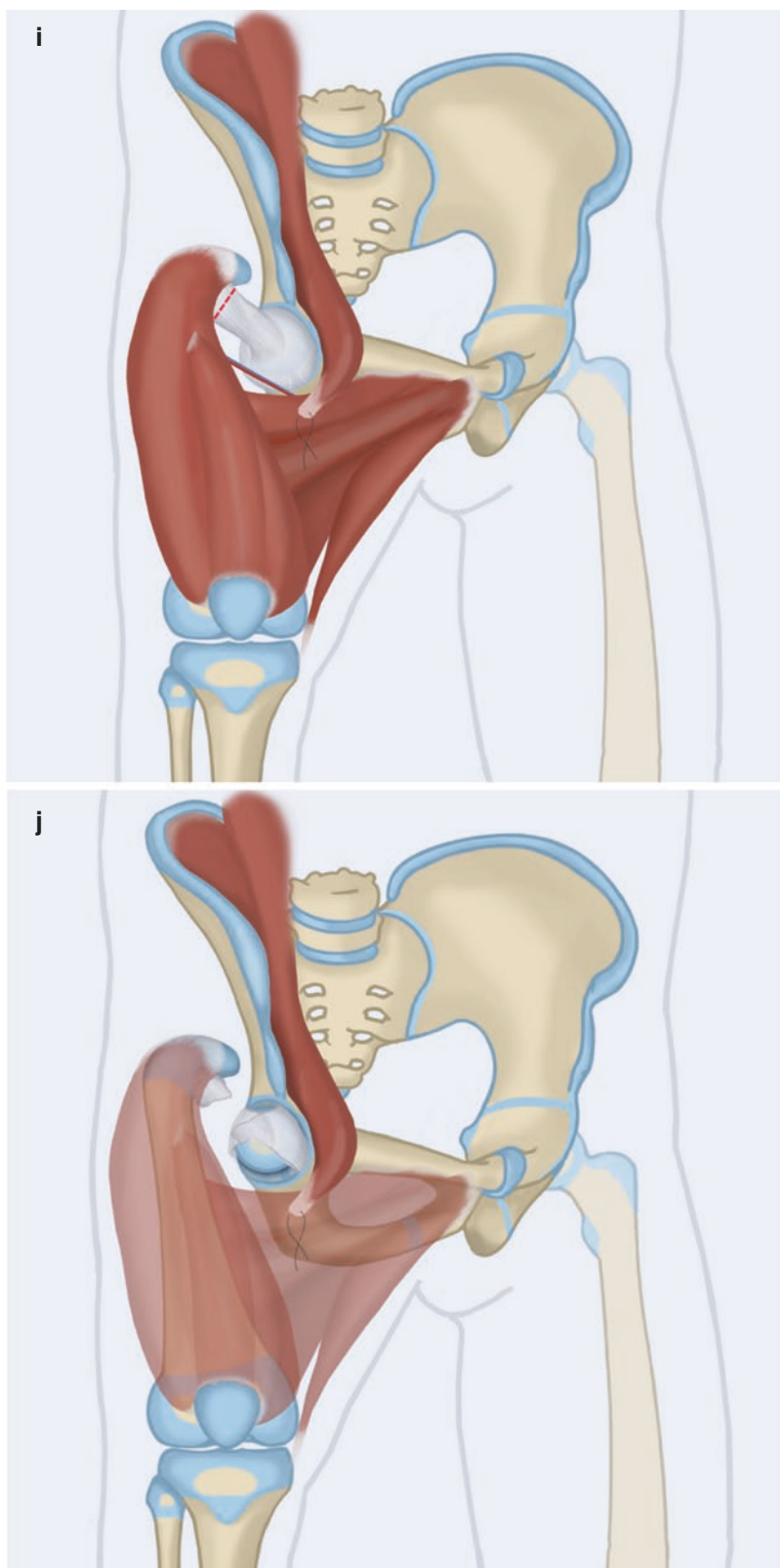


Fig. 35.10 (continued)

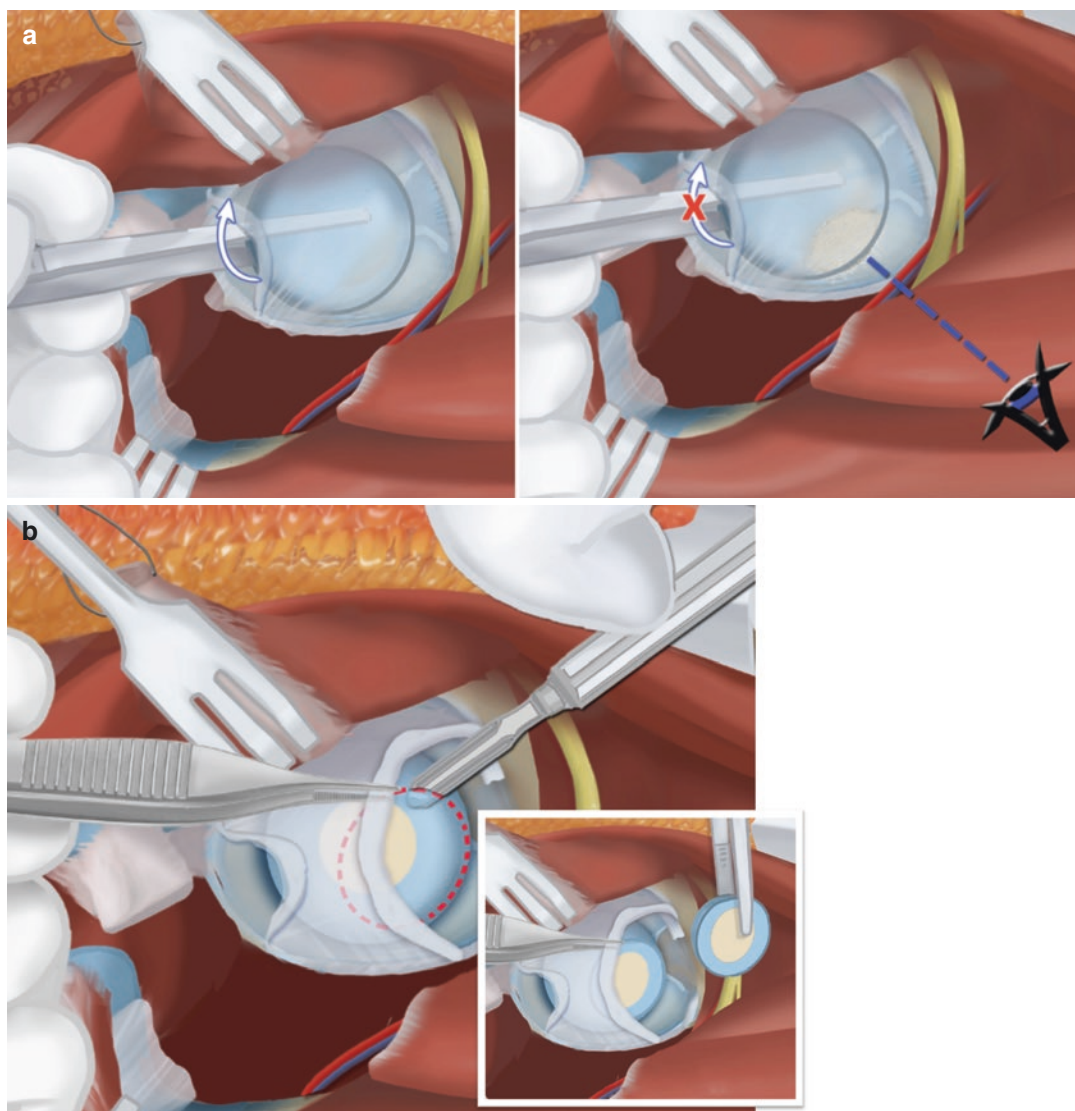


Fig. 35.11 (a–x) SUPERhip2 bony procedures: see steps of surgery corresponding to each figure. (© 2014 The Paley Foundation, with permission. All rights reserved)

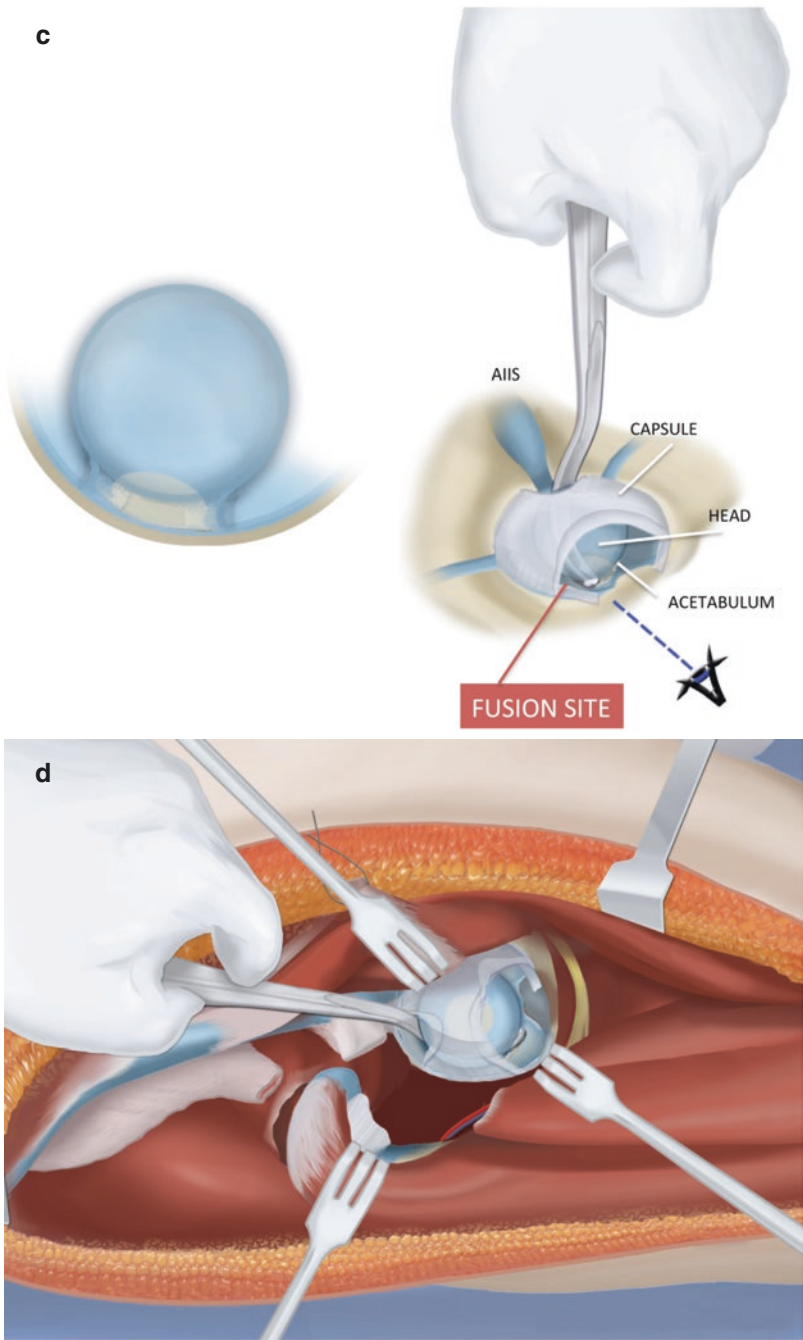


Fig. 35.11 (continued)

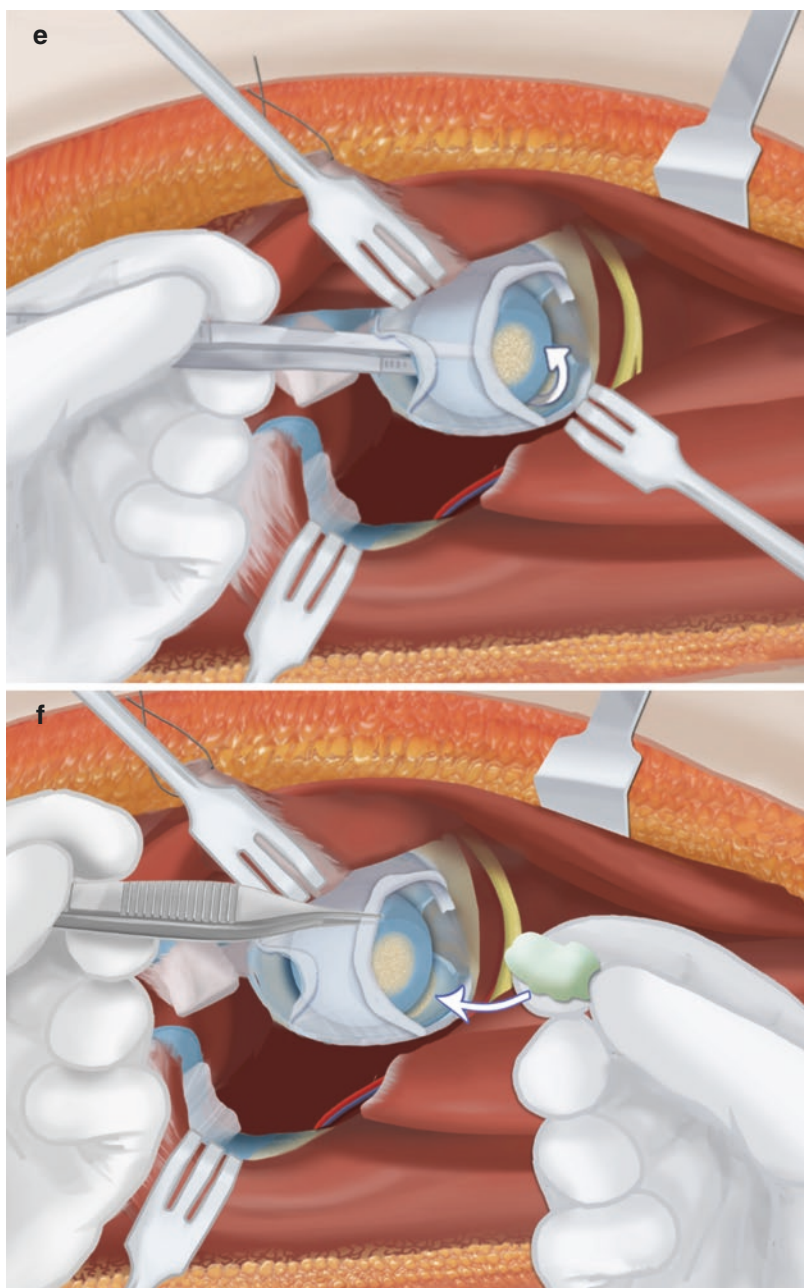


Fig. 35.11 (continued)

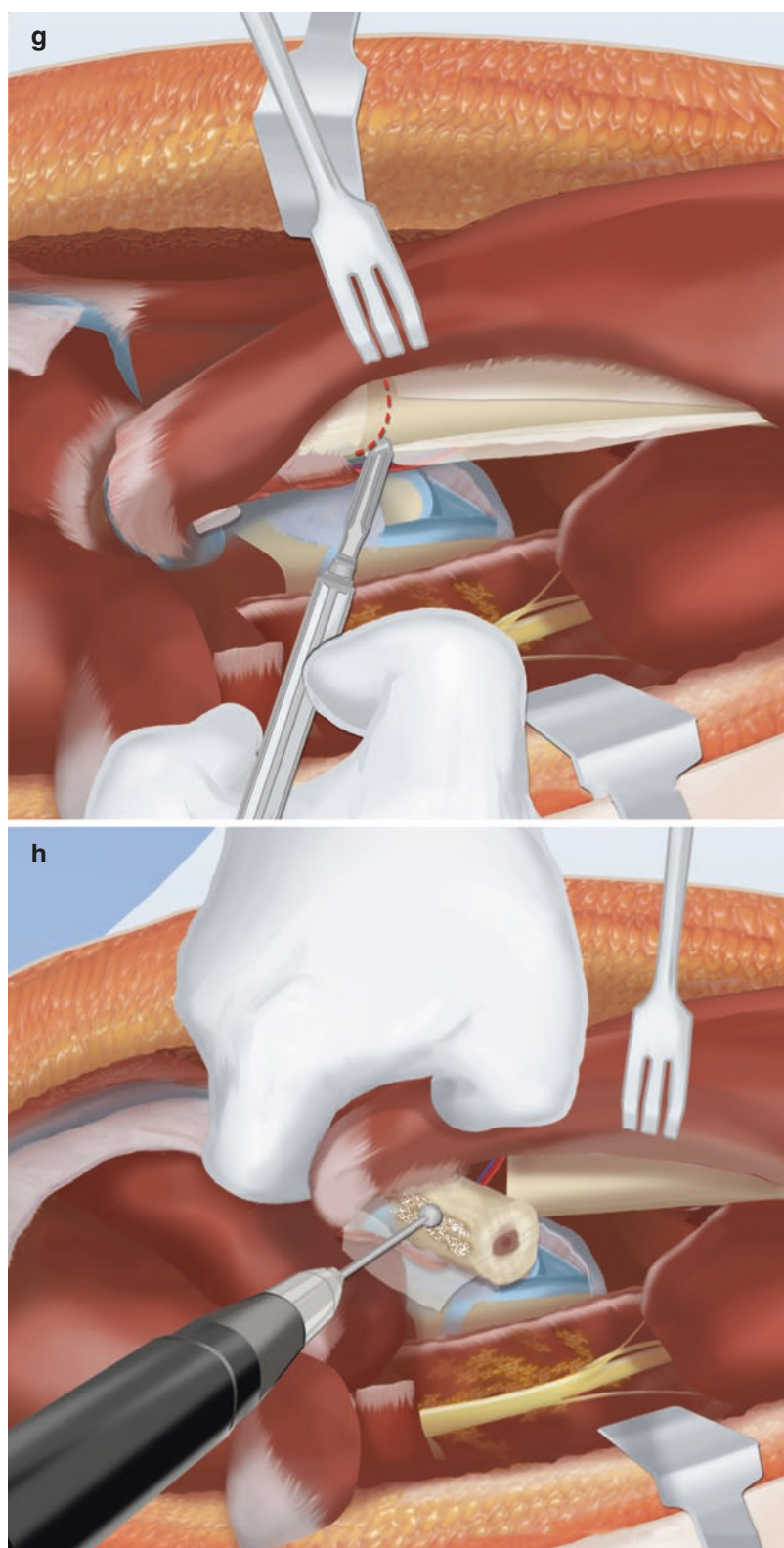


Fig. 35.11 (continued)

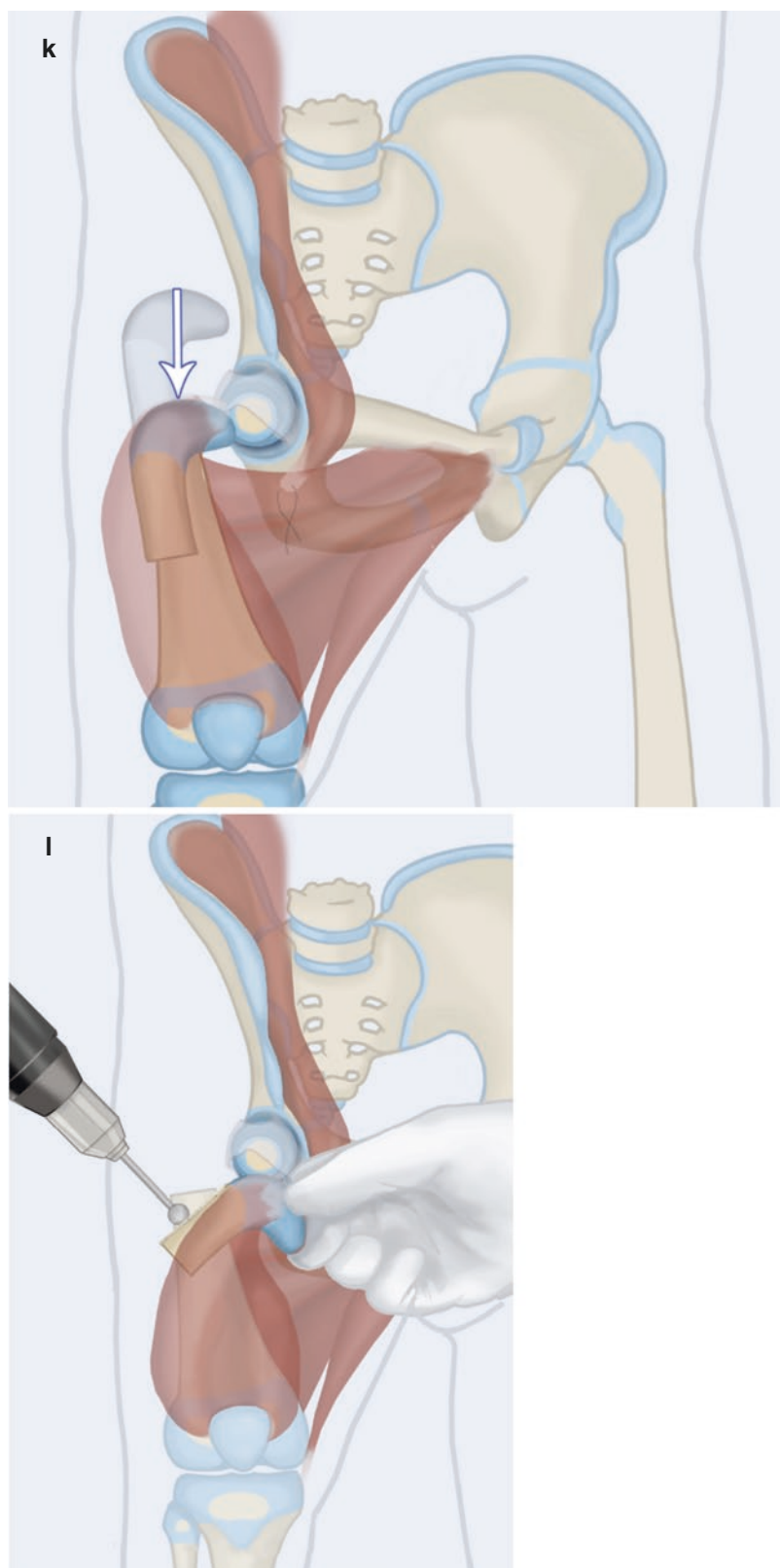


Fig. 35.11 (continued)

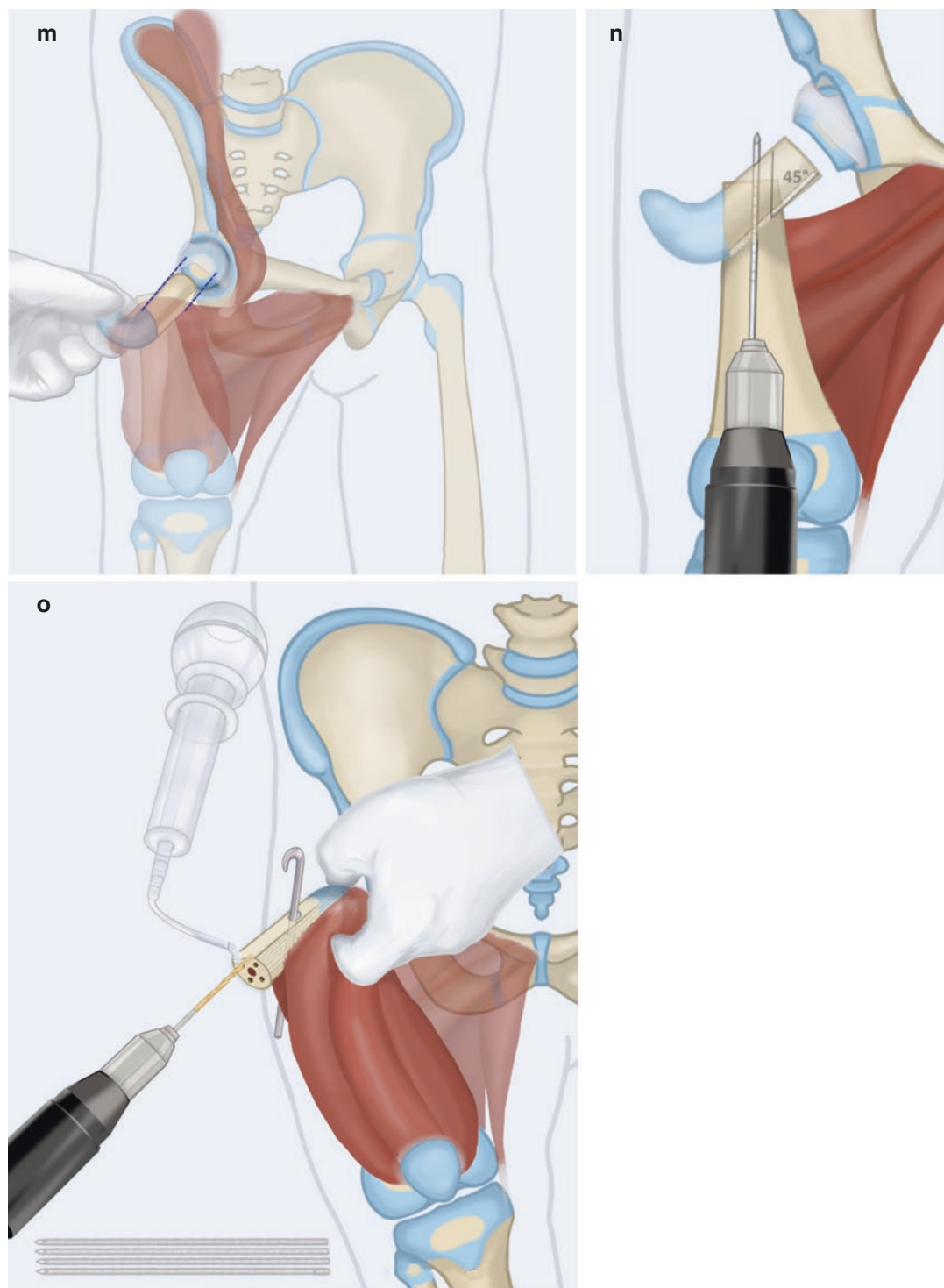


Fig. 35.11 (continued)

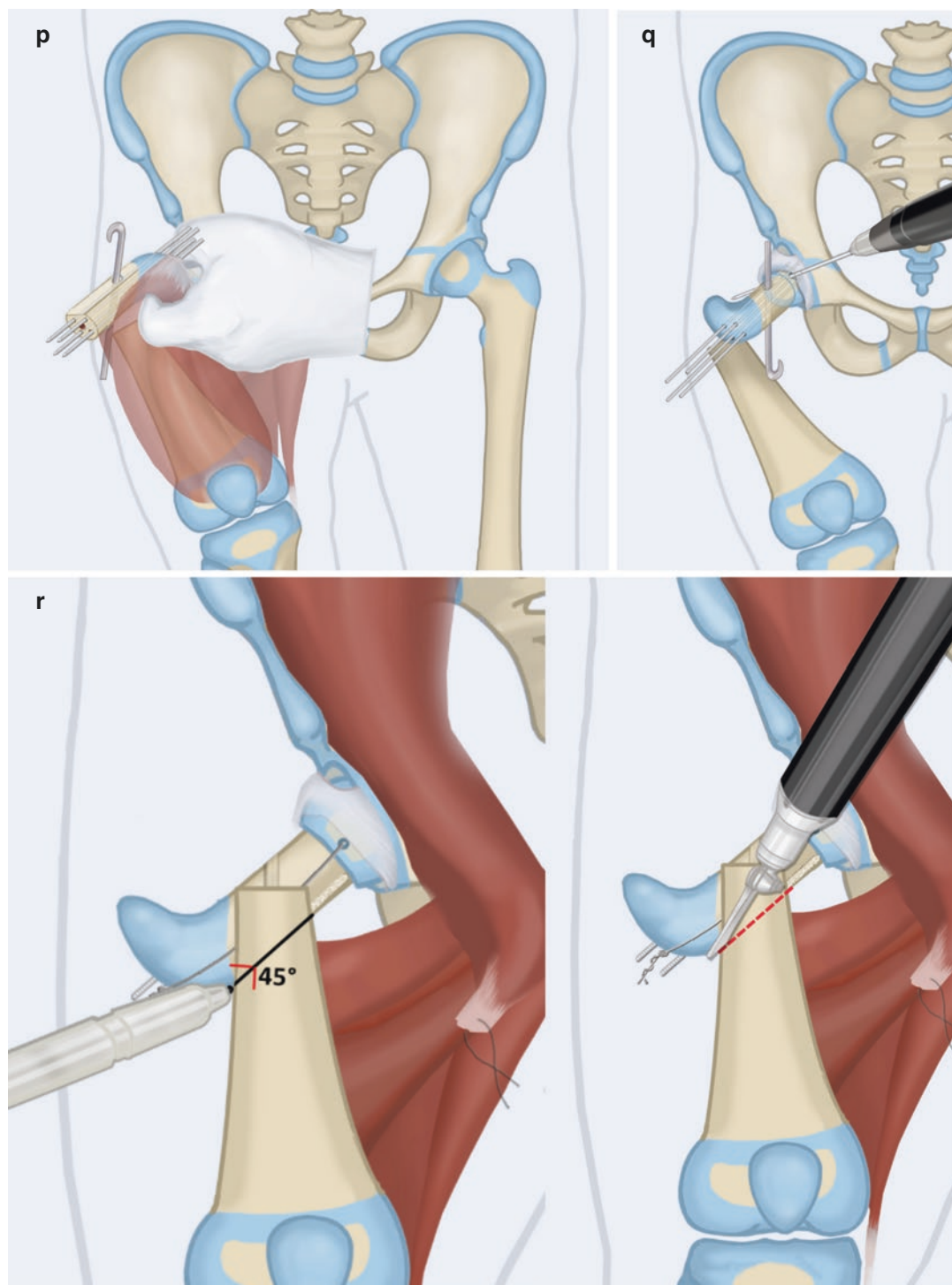


Fig. 35.11 (continued)

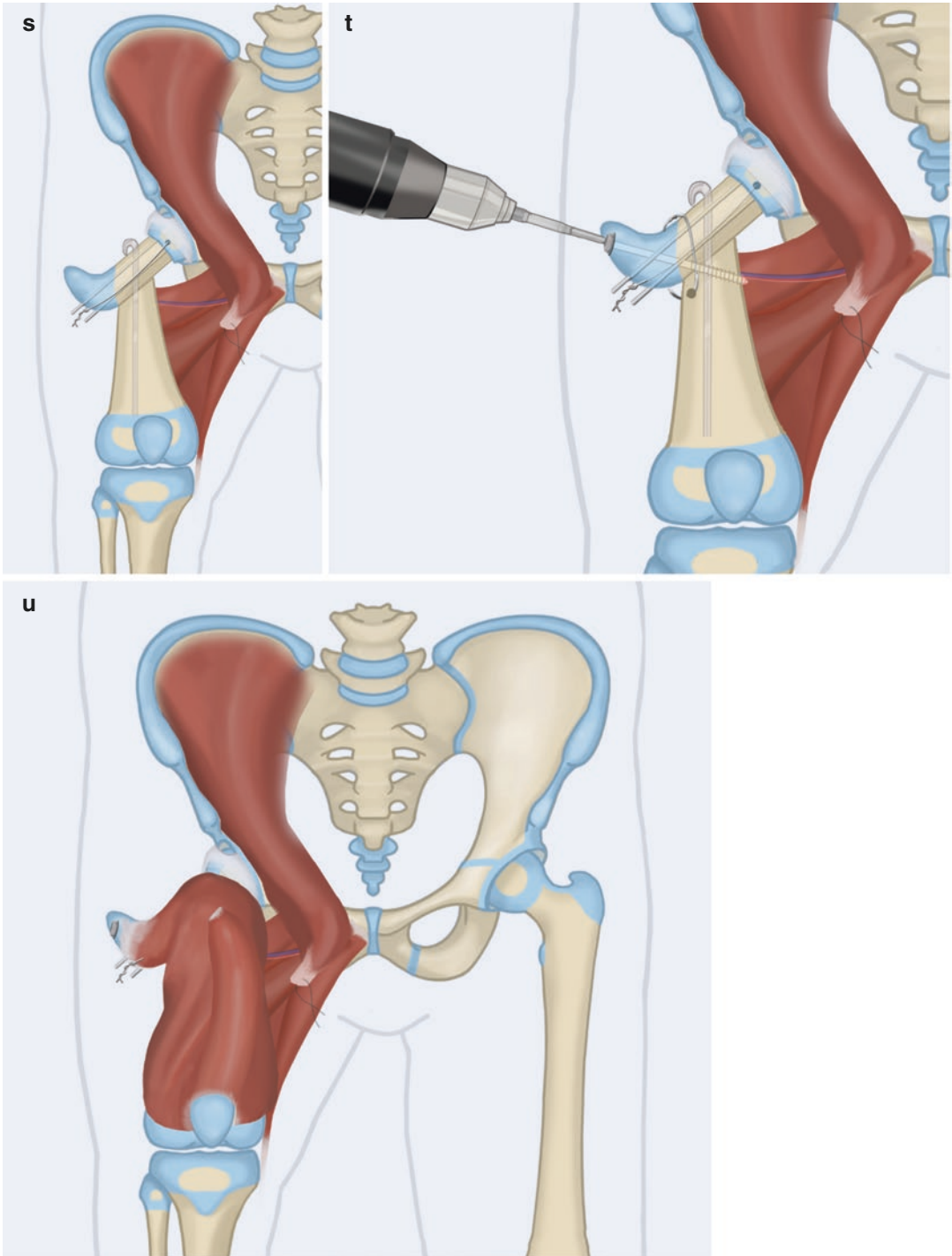


Fig. 35.11 (continued)

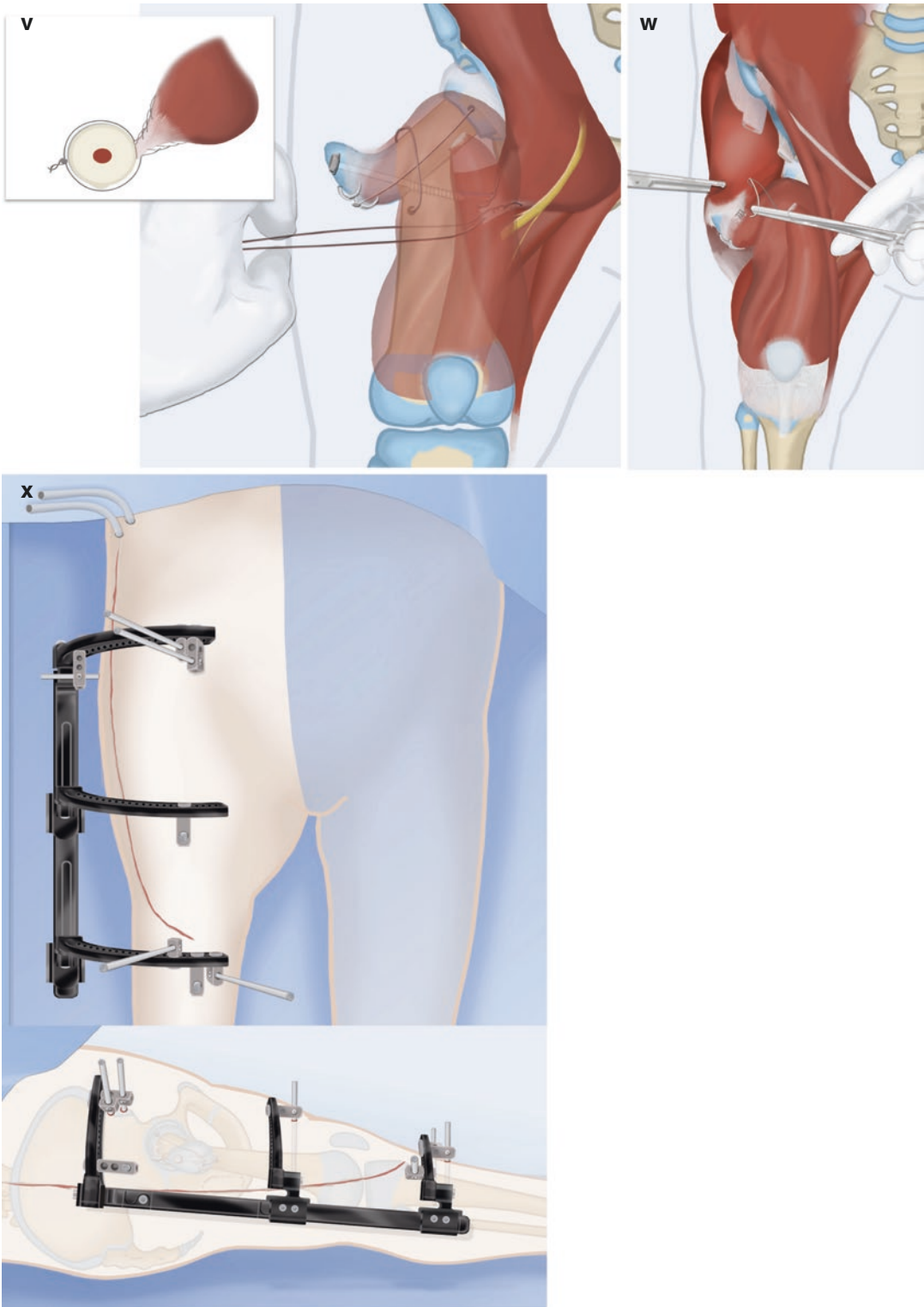
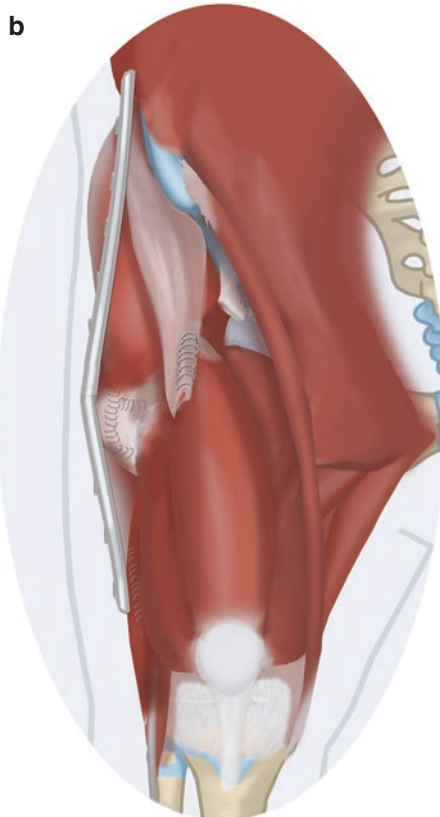
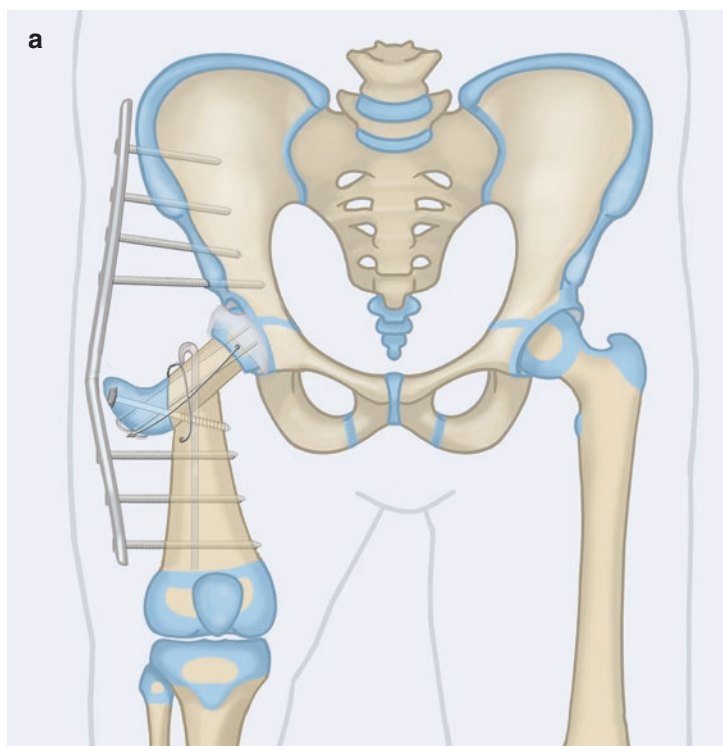


Fig. 35.11 (continued)

Fig. 35.12 (a, b) Use of an internal external fixator to temporarily arthrodese the hip. See steps of surgery corresponding to each figure. (© 2014 The Paley Foundation, with permission. All rights reserved)



15. *Break fusion site.* If the femoral head has a fusion site, identify the location of this site (opposite the ischium) and break this fusion using a small curved instrument (see Fig. 35.11c, d). Place bone wax on the exposed bone of the acetabulum and rotate the exposed bone of the femoral head outward (see Fig. 35.11e, f).
16. *Quadriceps elevation.* The quadriceps muscle is the vascular pedicle of the new femoral neck (see Fig. 35.11g). Therefore care should be taken to minimize dissection of this muscle off of the upper femur. The quads can be removed at the linea aspera and off the lateral wall of femur. It should not be dissected subperiosteally off of the anterior or medial aspects of the femur (see Fig. 35.11h).
17. *Femur osteotomy.* The femur can now be cut in the subtrochanteric region. The lateral wall of the femur is burred flat (see Fig. 35.11h).
18. *Remove bump.* The bump under the ischium can now be removed.
19. *Femoral neck mobilization.* The only tether at this point on the new femoral neck should be the quadriceps muscle and the femoral nerve (see Fig. 35.11m).
20. *Pre-drill femoral neck.* Pre-drill a 3.2 mm hole at 45° to the femoral neck as lateral as possible and as central as possible (see Fig. 35.11n). Insert a temporary 3.2 mm Rush rod and then predrill the femoral neck with three or four 1.5 mm cortical drill holes (see Fig. 35.11o). Insert two threaded and two nonthreaded k-wires (see Fig. 35.11p).
21. *Circlage wire.* Insert one 20 gauge wire through the femoral head (see Fig. 35.11q).
22. *Femoral neck to head connection.* Reduce the femur to the femoral head and advance the 4 wires into the femoral head to gain fixation. Pass the circlage wire under the quads and secure it by twisting the wire to compress the neck to the head.
23. *Knee flexion contracture.* If the knee joint has a flexion contracture a posterior capsu-
- lotomy with peroneal nerve decompression and biceps and gastrocnemius tendon releases is done. After the knee is fully straight it is pinned. This affects the amount of femoral shortening.
24. *Distal femur shortening osteotomy.* Overlap the bone ends and mark a 45° line to cut the femur. Internally rotate the distal femur 10° so that the cut is anteverted. Make the cut so that it shortens sufficiently to allow the bone ends to come to be reduced (see Fig. 35.11r).
25. *Rush rod length.* Pre-measure the length of the rod by predrilling into the distal femur. Cut a rod to the correct length.
26. *Insert Rush rod.* Insert the Rush rod antegrade to reduce and fix the neck to the shaft (see Fig. 35.11s).
27. *Second circlage.* Add another circlage to fix the trochanter to the femur. Make sure it passes under the quadriceps so as not to strangle the muscle pedicle (see Fig. 35.11t).
28. *More fixation.* A screw can also be added between the trochanter and the femur (see Fig. 35.11t).
29. *Psoas transfer.* Pass the psoas tendon distally and fix to the femur with a suture (see Fig. 35.11u, v).
30. *Reattach abductors.* Suture the abductor tendon to the greater trochanter. If it does not reach then do an abductor slide (see Fig. 35.11w).
31. *Temporary arthrodesis of hip with external fixation.* At this juncture decide how to temporarily arthrodesis the hip with either external fixation (see Fig. 35.11x) or internal fixation (see Fig. 35.12). With external then the wound is closed first and three pins are inserted into the pelvis, one in the femur and three in the tibia (see Fig. 35.11x).
32. *Temporary arthrodesis of the hip with internal fixation.* This is done using a locking plate to span the hip with locking screws into the lateral wall of the ilium and the femur (see Fig. 35.12).

33. *Removal of temporary arthrodesis fixation.* The temporary arthrodesis of the hip, external or internal, remains in place for 4 months and is then removed. By then union should have occurred both at the subtrochanteric osteotomy site and the femoral head neck junction.

Postoperative Imaging

Case 1 Plain radiographs are taken after the SUPERhip procedure to evaluate the healing of the pelvic osteotomy and femur osteotomy (see Fig. 35.3e). Subsequent lengthening surgery a year later is followed with plain radiography (see Fig. 35.3f, g) and clinically (see Fig. 35.3h).

Case 2 Plain radiographs are taken after the SUPERhip procedure to follow the ossification of the femoral neck and healing of the pelvic and femoral osteotomies. Standing radiographs also follow the progression of growth and discrepancy (see Fig. 35.4d–f). A year later the femur can be lengthened (see Fig. 35.4g, h). Several years later it can be lengthened a second time (see Fig. 35.4i, j).

Case 3 Plain radiographs are taken after the SUPERhip procedure to follow the healing and growth of the femur (see Fig. 35.5c). Femoral lengthening can be done one or more years later (see Fig. 35.5d, e).

Case 4 Plain radiographs are followed during the temporary arthrodesis period (usually 4 months) to assess for union at the subtrochanteric osteotomy and at the femoral head-neck junction (see Fig. 35.6c). The temporary arthrodesis external fixator is removed once union is achieved and growth and discrepancy are followed with standing radiographs (see Fig. 35.6d). Radiographs to follow lengthening and the hip are done at intervals (see Fig. 35.6e, f).

Pearls and Pitfalls

SUPERhip

- Pay careful attention to soft tissue handling, making sure the subcutaneous flaps are cleanly dissected to preserve their integrity and prevent fat necrosis.
- The lateral femoral cutaneous nerve is usually found just under the sartorius fascia and originates from deep to the inguinal ligament.
- The femoral nerve lies on the anteromedial side of iliopsoas muscle. The tendon lies posteromedial.
- Do not dissect distal or deep to the piriformis tendon to avoid interrupting the inferior gluteal anastomosis with the medial femoral circumflex artery.
- The apophysis should be split with a single continuous cut, pushing hard down to bone. Multiple passes will piecemeal the apophyseal cartilage.
- Palpate the back of the greater trochanter while placing the chisel and blade plate to make sure they stay perpendicular to its posterior border in the sagittal plane.
- The extent of the flexion and adduction deformity should be fairly evident by the orientation of the blade plate to the uncut femur. Greater than 45° of flexion deformity and up to 90° of varus deformity is not uncommon.
- Test the flexion of the hip and if obligatory external rotation occurs it is due to femoro-acetabular impingement. This requires shaving more bone off of the anteromedial aspect of the proximal femur (see Fig. 35.8m). This can weaken the cartilage bone connection between the femoral epiphysis and the subtrochanteric bone. To protect this a circlage wire can be used between the greater trochanter and the bone (drill anteroposterior into the cartilaginous trochanter and the bone for passage of the wire).
- Place the guide wire in the cannulated plate to help guide the rotational correction, BMP hole placement, and determining femoral anteversion

- Make sure that the hole drilled for BMP2 insertion does not connect with the hip joint. Also make sure to plug the lateral entry hole with bone wax. This will prevent heterotopic ossification.
- Placement of the guidewire into the center of the femoral neck is perhaps the most difficult step. Incorrect placement will cause the blade of the plate to be maloriented or even to be intra-articular. If you meet a lot of resistance when introducing the cannulated chisel it may mean that the chisel is not following the guide wire and is notching or bending this wire.
- It is important to shorten the femur adequately to avoid dislocation or stiffness of the hip joint.
- For the Paley modification of the Dega, be careful not to enter the hip joint or the triradiate cartilage with the posterior distal part of the cut. This can be avoided by staying as close to the sciatic notch as possible and not going to distal. Do not cut across the triradiate cartilage otherwise a partial growth arrest may occur.

SUPERhip2

- Do not strip the quadriceps off of the upper femur except on the lateral side. The quads are the vascular pedicle of the new neck.
- Do this procedure at an older age than the SUPERhip. The SUPERhip can be done as young as age 2. The SUPERhip2 should be deferred to age 3 or 4 depending on the size of the femur.
- Despite best efforts union of the neck to head site may not occur.
- Despite best efforts the femoral head may fuse back to the acetabulum.
- This procedure is technically extremely difficult and is one order of magnitude harder than the SUPERhip procedure. Become proficient at the SUPERhip before considering taking on an SUPERhip2.

Indications and Contraindications (Table 35.1)

Table 35.1 SUPERhip and SUPERhip2 procedures for congenital femoral deficiency: Surgical indications and contraindication

<i>Indications</i>	
The SUPERhip procedure is indicated for Paley type 1 congenital femoral deficiency (CFD) where there is a marked coxa vara (real or apparent) and the other associated deformities. Most patients who need the SUPERhip have Paley type 1b. There is a subgroup of Paley type 1a referred to as 1a ₃ that have similar deformities to the type 1b without the delayed ossification of the neck or subtrochanteric regions. Another indication are the congenital coxa vara patients. They all have an associated abduction contracture. The abductor slide and TFL release are essential in order to be able to fully correct the coxa vara. Bone morphogenic protein may help, especially in the congenital coxa vara that has the inverted Y delayed ossification region	
Other conditions that lead to chronic severe deformation of the proximal femur such as fibrous dysplasia, osteogenesis imperfecta, rickets, and certain dysplasias are also good indications for part or all of this technique	
The SUPERhip2 procedure is indicated primarily for patients with CFD type 2a or 2b. While it can be used for CFD type 3, those patients have such severe discrepancy that they are better candidates for a rotationplasty than for a SUPERhip2	
SUPERhip2 can also be used for other situations with a femoral neck nonunion but with preservation of the femoral head. These can include post-traumatic, post-infectious, and post tumor resection	
While most patients undergoing this procedure are doing so as a preparatory surgery to limb length equalization surgery, the SUPERhip procedure is still indicated in patients who choose to have a Syme's amputation for Paley type 1b. While the amputation with prosthetic fitting will obviate the need for limb length equalization surgery, it does not address the hip deformity and the limitations and problems created by this deformity, including more problematic and bulky prosthetics, late arthritis of the hip, limitation of abduction and other range of motion and cosmetic. The SUPERhip is still an excellent option in these patients notwithstanding the Syme's amputation	
<i>Contraindication</i>	
Perhaps the one contraindication for a SUPERhip procedure is if one is considering performing a rotationplasty at a later time. The amount of dissection for the SUPERhip procedure is quite large. A previous SUPERhip dissection can complicate the viability of the skin and muscle flaps created with rotationplasty	

Acknowledgements The author wishes to thank Pamela Boullier Ross, who created all of the illustrations used in this chapter. The author would also like to thank the Paley Foundation for funding the cost of the illustrations and for giving permission to Springer for their use in this chapter.

References

1. Paley D. Lengthening reconstruction surgery for congenital femoral deficiency. In: Herring JA, Birch JG, editors. *The child with a limb deficiency*. Rosemont, IL: American Academy of Orthopaedic Surgeons; 1998. p. 113–32.
2. Paley D, Chong DY, Prince DE. Congenital femoral deficiency reconstruction and lengthening surgery. In: Sabharwal S, editor. *Pediatric lower limb deformities, principles and techniques of management*. Heidelberg: Springer; 2016. p. 361–425.
3. Eidelman M, Jauregui JJ, Standard SC, Paley D, Herzenberg JE. Hip stability during lengthening in children with congenital femoral deficiency. *Int Orthop*. 2016;40(12):2619–25.
4. Paley D. Treatment of congenital femoral deficiency. In: Weisel SW, editor. *Operative techniques in orthopaedic surgery*. 2nd ed. Philadelphia: Lippincott Williams & Wilkins; 2015. p. 1532–51.
5. Paley D, Guadro F. Lengthening reconstruction surgery for congenital femoral deficiency. In: Kocaoğlu M, et al., editors. *Advanced techniques in limb reconstruction surgery*. Berlin: Springer; 2014. p. 245–99.
6. Paley D, Robbins CA. Congenital femoral deficiency: Paley type 1b and Paley type 1c. In: Rozbruch R, Hamdy R, editors. *Limb lengthening and reconstruction surgery case atlas*. Cham: Springer; 2015. p. 395–404.
7. Paley D, Standard SC. Lengthening reconstruction surgery for congenital femoral deficiency. In: Rozbruch SR, Ilizarov S, editors. *Limb lengthening and reconstruction surgery*. New York: Informa; 2007. p. 393–428.
8. Paley D, Standard SC. Treatment of congenital femoral deficiency. In: Wiesel S, editor. *Operative techniques in orthopaedic surgery*. Philadelphia: Lippincott Williams & Wilkins; 2010. p. 1202–23.
9. Paley D. Progress in and from limb lengthening. In: *Current progress in orthopedics*. Mumbai: Tree Life Media, Kothari Medical Subscription Services Pvt Ltd; 2014. p. 55–80.
10. Paley D, Robbins CA. Congenital femoral deficiency: Paley type 2a. In: Rozbruch SR, Hamdy R, editors. *Limb lengthening and reconstruction surgery case atlas*. Cham: Springer; 2015. p. 405–20.